

AMCoR

Asahikawa Medical College Repository <http://amcor.asahikawa-med.ac.jp/>

Journal of Arthroplasty (2007 Jan) 22(1):57-64.

Tight fit technique in primary hybrid total hip arthroplasty for patients with hip dysplasia

Ito, Hiroshi ; Hirayama, Teruhisa ; Tanino, Hiromasa ;
Matsuno, Takeo ; Minami, Akio

TITLE

TIGHT FIT TECHNIQUE IN PRIMARY HYBRID TOTAL HIP ARTHROPLASTY FOR
PATIENTS WITH HIP DYSPLASIA

ABSTRACT

This paper presents the mid-term results of hybrid total hip arthroplasty for patients with hip dysplasia using a tight fit technique for the femoral component. We followed 113 hips in 99 patients for a mean of 11 years. All final femoral rasps used in this study over-rasped by 0.5 – 1.0 mm for stem insertion, resulting in relatively thin cement mantles. Both components of one hip were removed due to infection. The other 5 acetabular components were revised for osteolysis, recurrent dislocation, or dislodgement of the polyethylene liner. No femoral component was revised for aseptic loosening. We conclude that the tight fit technique using a canal-filling stem may produce good long-term results for patient with hip dysplasia.

Key words: hybrid total hip arthroplasty, cemented femoral component, cement mantle, tight fit technique, mid-term follow-up

INTRODUCTION

Many laboratory, clinical and retrieval studies have reported that cement mantles of femoral components should have a minimal thickness of 2 to 4 mm, and should be complete [1-8]. These studies suggested that femoral osteolysis with or without loosening of the implant would likely occur when the cement mantles are thin, partially deficient or include voids.

On the other hand, Langlais et al [9] showed good clinical results with a thin cement mantle technique using two French-designed cemented femoral components, the Charnley-Kerboull [10-12] and the Ceraver Osteal [13,14], which are both intended to fully occupy the medullary canal of the femur. Skinner et al [15] also reported good clinical results with this technique using the Freeman cobalt-chrome femoral component. The final diameter of the reamer they used was the same or 2 mm greater than that of the final prosthesis.

Currently, the ideal thickness of the cement mantle for the femoral component is controversial. Total hip arthroplasty for osteoarthrosis secondary to developmental dysplasia of the hip presents specific problems including a narrow femoral canal [16]. A tighter fitting with use of the femoral component as large as possible may be important for these patients. We have used consecutively smaller final femoral rasps than those recommended by the manufacturer in hybrid total hip arthroplasty since 1987. This technique might result in thinner cement mantles. The purpose of this study was to evaluate the intermediate-term follow-up results of the tight fit technique for the patients with hip dysplasia, and to investigate whether this technique resulted in a high failure rate.

MATERIALS AND METHODS

Between March 1987 and December 1997, 140 consecutive primary hybrid total hip arthroplasties were performed in 125 patients to treat advanced osteoarthritis secondary to developmental dysplasia of the hip. Sixteen patients (17 hips) died before 7 years' follow-up. Five patients (5 hips) became bedridden and were too ill to return for follow-up evaluation. Five patients (5 hips) were lost to follow-up. These 27 total hip arthroplasties were well-fixed at the previous follow-up and these patients were excluded from the study. The remaining 113 hips in 99 patients were available for clinical and radiographic review. The average duration of follow-up was 11.0 years (range, 7.0–17 years). The average age at the time of the index operation was 62 years (range, 26–88 years). The average weight was 56 kg (range, 41–95 kg). Twelve patients were men and 77 were women. There were 55 right hips and 58 left hips. During the same period, cementless total hip arthroplasties were performed for patients under the age of 55 with good femoral cortical bone quality.

All of the procedures were performed through the posterolateral approach without trochanteric osteotomy. A Harris Precoat, Precoat Plus, or CDH Precoat stem (Zimmer, Warsaw, IN) was used in 91 hips (Fig. 1A-C). A CDH stem was used in 8 hips, a Small stem in 11 hips, a Small Plus stem in 33 hips, a Medium stem in 30 hips, a Large stem in 8 hips, and a Large Plus stem in one hip. Elite Plus stem (DePuy, Warsaw, IN) was used in 22 hips (Fig. 1D). A Size 1 stem was used in 3 hips, a Size 2 stem in 9 hips, a Size 3 stem in 6 hips, a Size 4 stem in 3 hips, and a Size 5 stem in one hip. The dimensions of the Precoat or Precoat Plus Small stem was almost equivalent to the Elite Plus Size 1 stem, the

Small Plus stem equivalent to the Size 2 stem, the Medium stem equivalent to the Size 3 stem, the Large stem equivalent to the Size 4 stem, and the Large Plus stem equivalent to the Size 5 stem respectively. The average surface roughness was 2.0 μm in the Harris Precoat stem, 2.2 μm in the Harris Precoat Plus or CDH Precoat stem, and 0.5 – 0.6 μm in the Elite Plus stem. We asked the manufacturers to provide femoral rasps for each final component, which over-rasped by 0.5 mm for the Harris Precoat, Precoat Plus and CDH Precoat stem, and 1.0 mm or less for the Elite Plus stem. All final femoral rasps used in this study for canal preparation over-rasped by 0.5 mm for the Harris Precoat, Precoat Plus and CDH Precoat stems, and by 1.0 mm or less for the Elite Plus stems. A so-called second-generation cementing technique was used with Simplex cement (Stryker-Howmedica-Osteonics, Mahwah, NJ) and a cement gun for the retrograde introduction of cement (Fig. 2). A methylmethacrylate plug was used in all but 12 hips. No plug was used in the first 4 hips, and in 8 subsequent hips, which had the CDH Precoat stem inserted, the canal was too narrow to accept a plug. We did not use vacuum-mixing, centrifugation, proximal cement pressurizers, or stem centralizers.

A titanium hemispherical Harris-Galante porous-coated (HGP) -1 or -2 acetabular component (Zimmer) was used in 91 hips and Duraloc 1200 acetabular component (DePuy) was used in 22 hips. An average of 3.5 screws (range, 2–6 screws) was used for fixation. The average outer diameter of the acetabular component was 51-mm (range, 40–64-mm). The diameter of the prosthetic femoral head was 22-mm in all hips.

Clinical evaluations were made according to the Harris hip scoring system [17].

An anteroposterior radiograph and a true lateral radiograph were made preoperatively and at

each follow-up examination. Preoperative, immediate postoperative, and all intermediate radiographs as well as those obtained at the latest follow-up visit were analyzed by orthopaedic surgeons other than the operating surgeon.

Cementing of the femoral stem was classified as Grade A, B, C-1, C-2, and D according to the method described by Mulroy et al [18]. The alignment of the femoral component was classified as valgus, neutral, or varus, as seen on anteroposterior radiograph. Femoral osteolysis was defined as areas of endosteal, intracortical, or cancellous loss of bone that were scalloped or had the appearance of bone destruction rather than disuse osteopenia. A linear radiolucent zone more than 2 mm wide was deemed as osteolysis. The dimensions and location of radiolucent lines at the bone-cement interface of the femoral component and osteolytic lesions were recorded according to the zones of Gruen et al [19]. The thickness of the femoral cement mantle was measured in 12 zones of the femur. If the outer border of the mantle was difficult to identify against cortical bone with no intervening cancellous bone, the thickness of the cortical bone seen on preoperative radiographs was used. The magnification ratio for each radiograph was determined by measuring the diameter of the prosthetic femoral head and dividing it by the known diameter of the femoral head. The canal filling ratio of the femoral component was defined as the percentage of component width to intramedullary width at the midpoint of the component on an anteroposterior radiograph taken within 1 month after surgery [20]. Loosening of the femoral component was defined using the criteria described by Harris et al [21]. Definite loosening was defined as migration of the component or cement mantle, bending or breakage of the stem, or cement fracture. Debonding of the cement-metal interface, as seen by a radiolucent line

of any width at this interface, was considered to indicate subsidence of the stem and was classified as loose.

The acetabular interface on the anteroposterior radiograph was divided into three zones as described by DeLee and Charnley [22]. The acetabular component was classified as migrated if there was a change of at least 4 mm in the horizontal or vertical position of the center of the component compared with that seen on the immediate postoperative anteroposterior radiograph [23]. Linear head penetration into the polyethylene liner was measured using the techniques described by Livermore et al [24].

Statistical analyses were performed using chi-square tests and Kruskal-Wallis test. Probability values less than 0.05 were considered significant. Kaplan-Meier survivorship analysis was used to calculate the probability of retention of the original prosthesis with 95% confidence intervals (StatView; SAS Institute Inc, Cary, NC).

RESULTS

At the time of the most recent follow-up, revisions had been performed in 6 hips in 6 patients. Both acetabular and femoral components of one hip with postoperative infection were simultaneously removed 10 months after index surgery. None of the femoral components was revised for aseptic loosening. Another 5 acetabular components were revised; one for osteolysis around the acetabular component, 3 for recurrent dislocation, and one for dislodgement of the polyethylene liner from the metal shell. The Kaplan-Meier survivorship analysis, with failure defined as revision surgery, demonstrated that the

probability of retention of the femoral component 15 years after surgery was 99% (95% confidence interval, 0.98–1.0), and that of the acetabular component 15 years after surgery was 94% (95% confidence interval, 0.91–0.97).

The Harris hip score increased from a preoperative average of 45 points (range, 24–78 points), to 86 points (range, 42–100 points) at the most recent follow-up.

One femoral component was revised because of infection, as described above. None of the other 112 femoral components showed possible, probable, or definite loosening at the most recent follow-up. The position of the femoral component was neutral in 68 hips, valgus in 40 hips, and varus in 5 hips. The cementing of the femoral component was grade A in 6, grade B in 26, grade C-1 in 38, grade C-2 in 41, and grade D in 2. Grade C-1 was mainly due to the presence of small voids, grade C-2 to the presence of a thin mantle of cement, and grade D to insufficient cement mantle distal to the tip of the stem. The cement thickness for 4 types of the femoral component (Table 1) and the cement thickness for 6 sizes of the femoral component (Table 2) indicated that cement mantles of the CDH Precoat stem were a little thinner than those of other stems, however, no significant difference was found in each zone. Relationship between 4 types of the femoral component and various factors was shown in Table 3. Although the mean canal filling ratio of the CDH Precoat stem was a little lower, no significant difference was found among 4 types of the femoral component. All femoral radiolucent lines were located in the most proximal zones (zones 1 and 7) and none of the femurs showed any radiolucent lines other than in the most proximal zones. Femoral osteolysis was also localized in zone 1 or 7. Ten hips had dislocated

posteriorly. Three of the 10 hips had undergone revision of the acetabular component for recurrent dislocation.

Six acetabular components were revised as described above. The average postoperative angle of abduction of 107 acetabular components at the most recent follow-up was 46° (range, 25° – 63°). Radiolucent lines were observed around 19 (18%) acetabular components. These lines were all 1 mm wide or less, occurred in zone 1 in 10 hips, zone 2 in 12 hips, and zone 3 in 7 hips. There were no sockets showing a continuous radiolucent line. Pelvic osteolytic lesions were observed adjacent to the acetabular component in 4 (4%) hips. Two of the 4 hips with pelvic osteolysis showed radiolucent lines around the corresponding femoral component. One involved an osteolytic area (12 by 15 mm) in zones 1 and 2, in which morcelled fresh-frozen bone allograft was performed 10.4 years after the index procedure. The average rate of head penetration into the polyethylene liner was 0.09 mm (range, 0–0.29 mm) per year.

One patient had mild sciatic nerve palsy, which resolved nearly completely within 18 months. There were no clinically evident pulmonary embolisms.

DISCUSSION

Thin or incomplete cement mantles have been reported to be responsible for irregular stress distribution, mantle fracture, stem debonding, osteolysis, and loosening [1-8]. Ebramzadeh et al [1] reported the results of 836 cemented femoral components at an average follow-up of 9 years, in which stems with a 2 to 5 mm-thick cement mantle in the proximal

medial region had a better outcome than those with a thicker or thinner cement mantle. Joshi et al [3] reported the results of 249 Charnley primary arthroplasties at a minimum follow-up of 10 years, in which significant factors reducing osteolysis were femoral cement mantles of 3 mm in all zones and a canal filling ratio of 60% to 70%. Valdivia et al [25] evaluated the cement mantle thickness of the femoral component using different designs by computer-assisted analysis, and reported that the mean mantle thickness was 3 to 4 mm, with significantly different variability between the stems. They also reported that the mean mantle thickness by region and segment was greater than 2 mm in most femoral components, and recommended at least 2 mm cement mantle thickness which requires sufficient intraoperative over-rasping or over-reaming of the femur.

On the other hand, good clinical results using a thin cement mantle technique have been reported. Nizard et al [13] reported that the survival rate of 187 Ceraver Osteal stems at 10 years was 99.2%. Kerboull [11] reported that 1% to 2% aseptic loosening of the CK mark I Charnley-Kerboull stem was observed at an average follow-up of 20 years. Skinner et al [15] reported that the survival rate of the cemented Freeman cobalt-chrome stem at 10 years was 97.2% in 92 hips in which the canal was over-reamed by 2 mm and 98.8% in 97 hips in which the canal was reamed to the same size as the prosthesis.

The thin cement mantle technique was introduced by Postel et al [26], and is widely used in France [9]. Langlais et al [9] introduced the design philosophy of the Charnley-Kerboull and the Ceraver Osteal stems, which includes very thin and sometimes incomplete cement mantles. They commented that the vigorous insertion of a canal-filling stem into doughy cement would produce a marked pressure increase at the cement-bone interface during stem insertion, and stronger initial mechanical interlocking at the

cement-bone interface could be obtained. Kerboul [10] recommended complete removal of the cancellous bone in the medullary canal before filling with cement and forcing in a well-fitting prosthetic stem that would almost fill the medullary cavity. Similarly, Witvoet [14] described the operative technique used with the Ceraver Osteal stem, in which they tried to fill the medullary femoral canal as much as possible with the largest possible stem, which requires boring the medullary cavity in a number of cases. They did not recommend trying to achieve a continuous cement mantle. These canal-filling stems require hammer blows to complete their insertion [26]. Skinner et al [15] reported two advantages of the thin cement mantle technique: first, if a prosthesis is used to pressurize the cement, a higher pressure is produced by the tighter fit, second, the tight fit immobilizes all the cement interfaces while the cement sets. Song, Goodman and Jaffe [27] showed that if intrafemoral pressure was measured continuously throughout cementation, stem insertion generated the highest pressure, suggesting that prior pressurization may be unnecessary. Skinner et al [15] commented that eliminating micromovement during this vital period has profound and long-lasting effects for 20 years. They concluded that it was incorrect to insert a femoral prosthesis with a thick and complete cement mantle. We think that the tighter fit of the femoral component is technically important for the patients with a narrow femoral canal and our results support these previous studies.

We agree that the ideal thickness of the cement mantle for the femoral component is controversial. Many studies have reported that a thin or incomplete cement mantle should be avoided [1-8,25]. However, Brown and Bargar [28] showed that 1.6 mm thin specimens demonstrated an increase in stress failure of 14% and an increase in strain failure of 30% compared with 3.2 mm thicker specimens. Hertzler et al [29] reported that the

fatigue crack growth rate did not depend on cement mantle thickness in an experimental study using a cyclic torsional loading system, in which constructs with 1 mm thin, 3 mm medium, or 7 mm thick cement mantles were used. The previous good results [11-15] and our results using the tight fit technique with relatively thin cement mantle coincide with these laboratory studies. We also agree that the ideal canal filling ratio is controversial. The thin cement mantle technique tends to require a high canal filling ratio. Joshi et al [3] reported that cement mantles of 3 mm in all zones of the femur and a canal filling ratio of 60% to 70% were favorable factors to reduce osteolysis. Kobayashi and Terayama [20] reported that a canal filling ratio of $\geq 75\%$ correlated positively with survival of the femoral component. The average canal filling ratio of 75.3% in this study was comparable to these previous studies. Although there have been no published reports describing the histology at the long-term bone-cement interface in relation to these canal filling stems, it is supposed that the mechanical load may be directly transmitted from the stem to bone favorably without compromising the cement.

Although each final femoral rasp we used was 0.5 – 1.0 mm larger than the inserted femoral component, the measured cement mantles were thicker than we expected. An average cement thickness in some zones was less than 2 mm, however, traditionally recommended cement thickness of greater than 2 mm was more frequently observed. Skinner et al [15] also reported that the mean cement thickness measured in various section levels of the stem was all 2mm or greater in the experimental cadaver study using the thin cement mantle technique. These results suggest that the thin cement mantle technique does not necessarily produce really “thin cement mantle”. Either the rasping technique leading to larger canal preparation or the pressure of the stem in a tight canal resulting in more

cement penetration into the bone might likely be responsible.

Langlais et al [9] described that French stems using the thin cement mantle technique, provided that their surfaces are polished, function well in the medium and long term, although the cement mantles are extremely thin and may be incomplete. The average surface roughness of the stem used in this study was 0.5 μm to 2.2 μm , suggesting that good results can be expected even if rougher surface stems are used. There may be various factors that can influence the early and long-term survival of the femoral component. In addition to the variables of cement mantle thickness and surface finish, additional variables such as stem geometry, offset, operative techniques, and patient population, may all play important roles in the durability of a femoral component.

Valdivia et al [25] reported that standard anteroposterior radiographs overestimated cement mantle thickness and underestimated deficiencies when compared with CT scan measurements by Gruen zones. We measured the thickness of the cement mantles only on plain radiographs, thus it is possible that we overestimated the thickness of the cement mantles, which was one weakness of this study. However, even if the cement mantles were thinner, our good results indicated the usefulness of this tight fit technique with relatively thin cement mantles.

We agree with Skinner et al [15] that a press-fit stem supplemented with cement is as good, if not better than other techniques. We believe that the intraoperative higher pressure on the cement by the tighter fit during stem insertion and the use of a canal filling stem in which the stem to bone load may be directly transmitted are the two most important advantages of this tight fit technique.

REFERENCES

1. Ebramzadeh E, Sarmiento A, McKellop HA, Linas A, Gogan W: The cement mantle in total hip arthroplasty: analysis of long-term radiographic results. *J Bone Joint Surg Am* 76:77, 1994
2. Fisher DA, Tsang AC, Paydar N, Millionis S, Turner CH: Cementmantle thickness affects cement strains in total hip replacement. *J Biomech* 30:1173, 1997
3. Joshi RP, Eftekhar NS, McMahon DJ, Nercessian OA: Osteolysis after Charnley primary low-friction arthroplasty: a comparison of two matched paired groups. *J Bone Joint Surg Br* 80:585, 1998
4. Kawate K, Maloney W, Bragdon CR, Biggs SA, Jasty M, Harris WH: Importance of a thin cement mantle: autopsy studies of eight hips. *Clin Orthop* 355:70, 1998
5. Kawate K, Ohmura T, Hiyoshi N, Natsume Y, Teranisni T, Tamai S: Thin cement mantle and osteolysis with a pre-coated stem. *Clin Orthop* 365:124, 1999
6. Ramaniraka NA, Rakotomanana LR, Leyvraz P-F: The fixation of the cemented femoral component: effects of stem stiffness, cement thickness and roughness of the cement/bone surface. *J Bone Joint Surg Br* 82:297, 2000
7. Ritter MA, Zhou H, Keating CM, et al: Radiological factors influencing femoral and acetabular failure in cemented Charnley total hip arthroplasties. *J Bone Joint Surg Br* 81:249, 1999
8. Star MJ, Colwell CW, Kelman GJ, Bullock RT, Wacker RH: Sub-optimal distal cement mantle thickness as a contributory factor in total hip arthroplasty femoral component failure: a retrospective analysis favouring distal cement centralisation. *J Arthroplasty* 9:143, 1994

9. Langlais F, Kerboull M, Sedel L, Ling RSM: Annotation: the 'French paradox'. *J Bone Joint Surg Br* 85:17, 2003
10. Kerboull M: The Charnley-Kerboull prosthesis. p. 13. In: Postel M, Kerboull M, Evrard J, Courpeid J (eds): *Total hip replacement*. Springer Verlag, Berlin etc, 1987
11. Kerboull M: L'arthroplastie totale de hanche. *Maîtrise Orthopédique* 83:6, 1999
12. Kerboull L, Hamadouche M, Kerboull M: Long term results of Charnley-Kerboull total hip replacement in patients younger than 50, p. 37 In: Caton J, Ferreira A, Picault C (eds): *Arthroplastie totale de hanche*. Lyon: Transit Communications, 2000
13. Nizard RS, Sedel L, Christel R: Ten year survivorship of cemented ceramic-ceramic total hip prostheses. *Clin Orthop* 282:53, 1992
14. Witvoet J: Long-term results of titanium alloy smooth cemented femoral stem. p. 237 In: Caton J, Ferreira A, Picault C (eds): *Arthroplastie totale de hanche*. Lyon: Transit Communications, 2000
15. Skinner JA, Todo S, Taylor M, Wang JS, Pinskerova V, Scott G: Should the cement mantle around the femoral component be thick or thin? *J Bone Joint Surg Br* 85:45, 2003
16. Jaroszynski G, Woodgate I, Saleh K, Gross A: Total hip replacement for the dislocated hips. *J Bone Joint Surg Am* 83:272, 2001
17. Harris WH. Traumatic arthritis of the hip after dislocation and acetabular fracture: treatment by mold arthroplasty. *J Bone Joint Surg Am* 51:737, 1969
18. Mulroy WF, Estok DM, Harris WH: Total hip arthroplasty with use of so-called second-generation cementing techniques: a fifteen-year-average follow-up study. *J Bone Joint Surg Am* 77:1845, 1995

19. Gruen TA, McNeice GM, Amstutz HC: "Modes of failure" of cemented stem-type femoral components: a radiographic analysis of loosening. *Clin Orthop* 141:17, 1979
20. Kobayashi S, Terayama K: Factors influencing survivorship of the femoral component after primary low-friction hip arthroplasty. *J Arthroplasty* 7(suppl):327, 1992
21. Harris WH, McCarthy JC Jr, O'Neill DA: Femoral component loosening using contemporary techniques of femoral cement fixation. *J Bone Joint Surg Am* 64:1063, 1982
22. DeLee JG, Charnley J: Radiographical demarcation of cemented sockets in total hip replacement. *Clin Orthop* 121:20, 1976
23. Russotti GM, Harris WH: Proximal placement of the acetabular component in total hip arthroplasty: a long-term follow-up study. *J Bone Joint Surg Am* 73:587, 1991
24. Livermore J, Ilstrup D, Morrey B: Effect of femoral head size on wear of the polyethylene acetabular component. *J Bone Joint Surg Am* 72:518, 1990
25. Valdivia GG, Dunbar MJ, Parker DA, et al: Three-dimensional analysis of the cement mantle in total hip arthroplasty. *Clin Orthop* 393:38, 2001
26. Postel M, Kerboull M, Evrard J, Courpeid J (eds): Total hip replacement. Springer Verlag, Berlin etc, 1987
27. Song Y, Goodman S, Jaffe R: An in-vitro study of femoral intramedullary pressures during hip replacement using modern cement technique. *Clin Orthop* 302:297, 1994
28. Brown SA, Bargar WL: The influence of temperature and specimen size on the flexural properties of P. M. M. A. bone cement. *J Biomed Mat Res* 18:523, 1984
29. Hertzler J, Miller MA, Mann KA: Fatigue crack growth rate does not depend on mantle thickness: an idealized cemented stem construct under torsional loading. *J Orthop Res*

20:676, 2002

LEGENDS TO FIGURES

Fig. 1. Photographs of four types of the femoral component.

- (A) CDH Precoat stem.
- (B) Precoat stem.
- (C) Precoat Plus stem.
- (D) Elite Plus stem.

Fig. 2. Preoperative and follow-up radiographs of the left hip of a 77-year-old woman.

- (A) Preoperative radiograph showed advanced osteoarthritis secondary to developmental dysplasia.
- (B) A Harris Precoat Plus stem was inserted with use of the tight fit technique. Postoperative radiograph taken one week after surgery showed 88% canal filling ratio.
- (C) Radiograph taken at 9-year follow-up examination showed slight atrophy of the femoral cortical bone. The patient had a good clinical result.

Figure 1A
[Click here to download high resolution image](#)




Figure 1B
[Click here to download high resolution image](#)




Figure 1C
[Click here to download high resolution image](#)

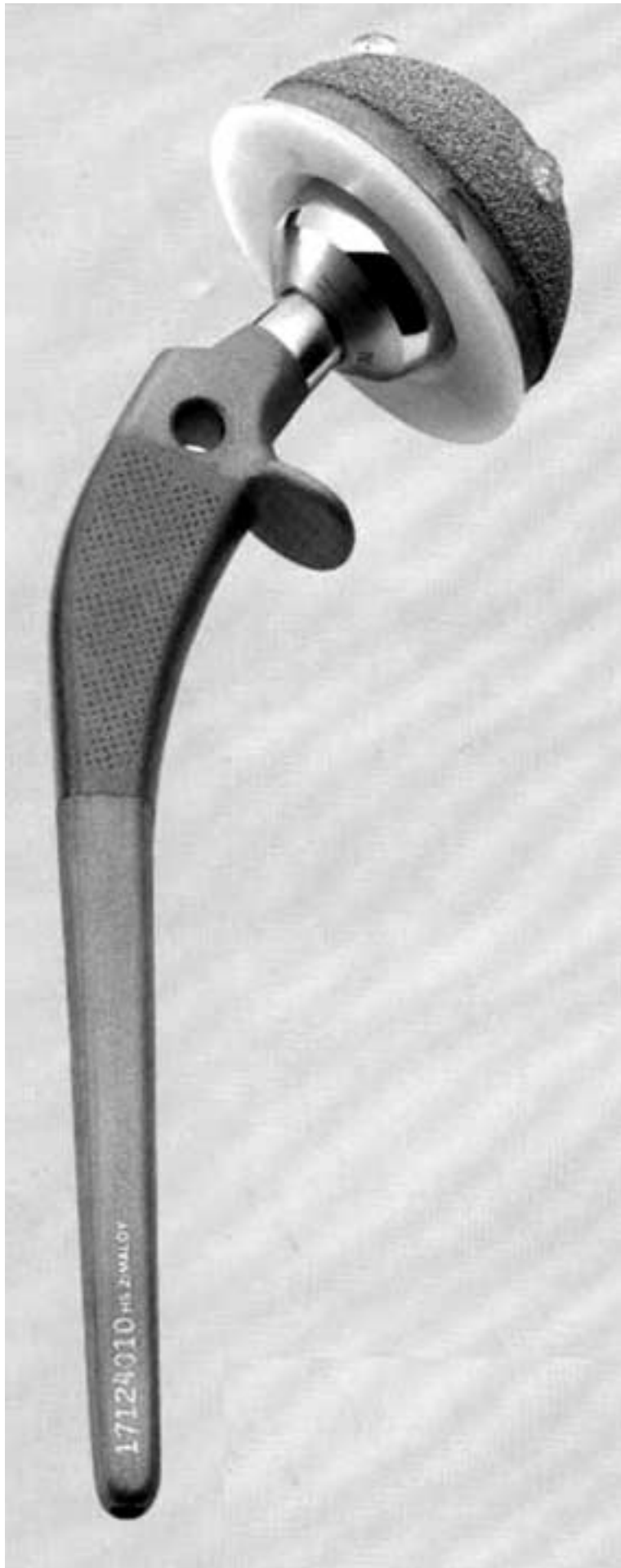

Figure 1D
[Click here to download high resolution image](#)

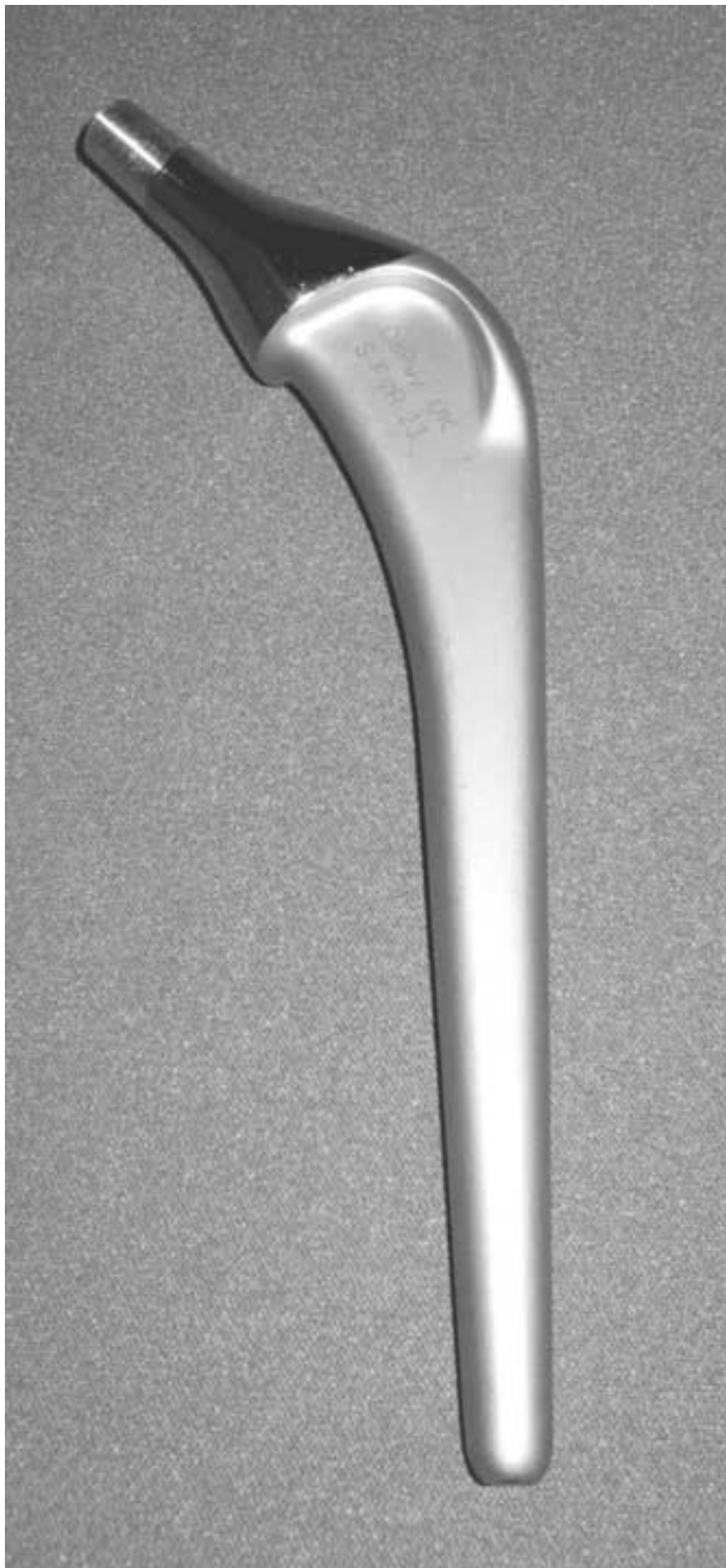

Figure 2A
[Click here to download high resolution image](#)

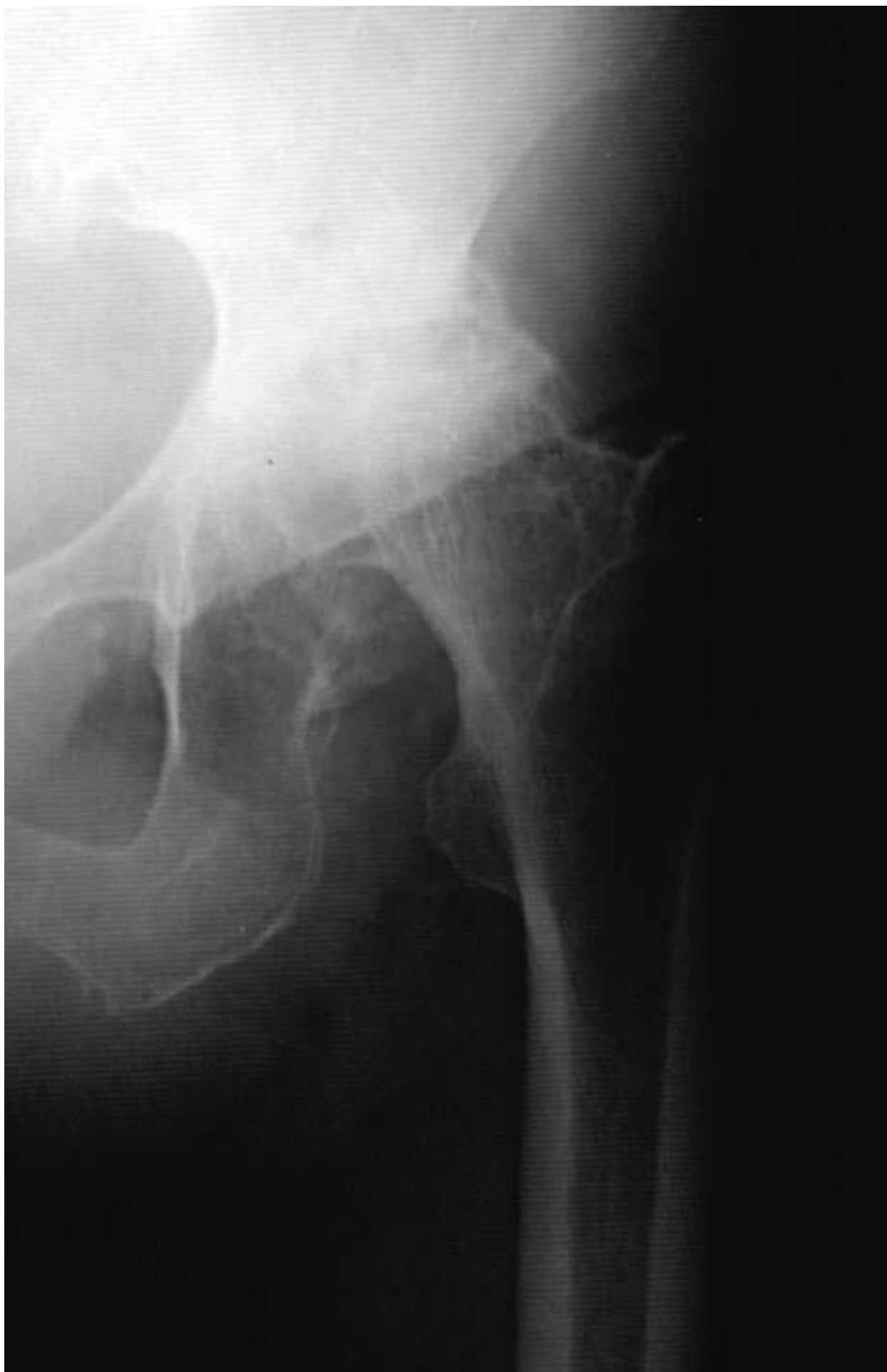

Figure 2B
[Click here to download high resolution image](#)

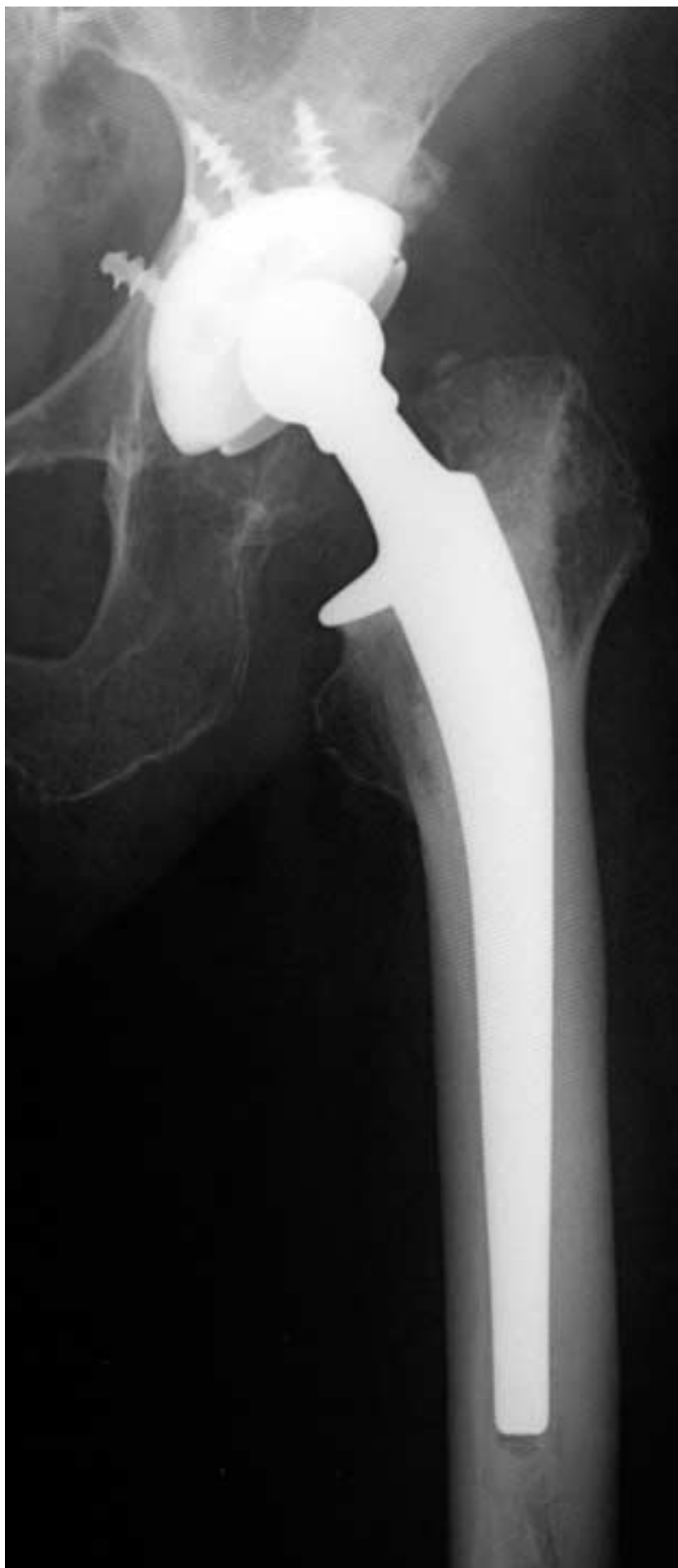

Figure 2C
[Click here to download high resolution image](#)

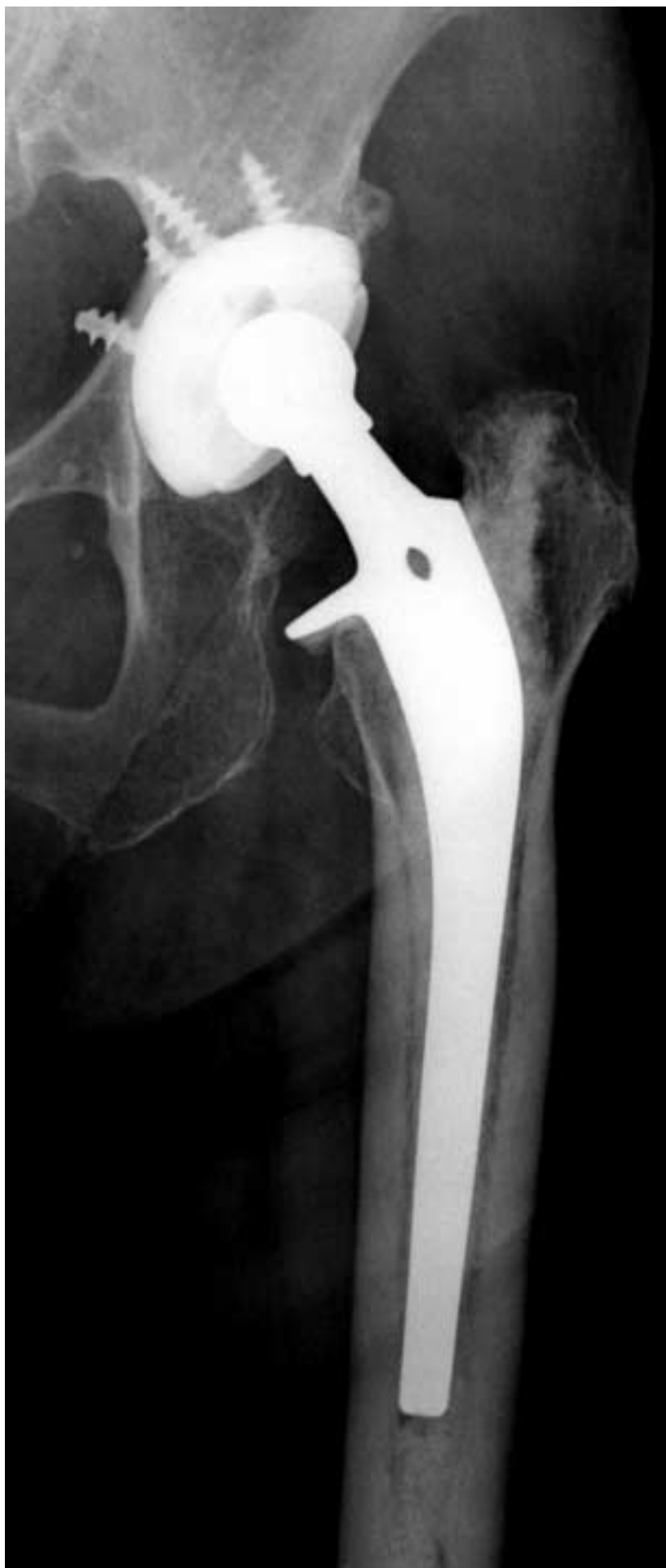

Table 1. Analysis of the cement thickness for four types of the femoral component

Femoral zone	Cement thickness (mm)*					P Value
	CDH Precoat (n = 8)	Precoat (n = 15)	Precoat Plus (n = 68)	Elite Plus (n = 22)	Total (n = 113)	
1	1.3 ± 0.8	2.0 ± 0.6	2.1 ± 0.7	2.2 ± 0.7	2.1 ± 0.8	.065
2	1.4 ± 0.9	1.7 ± 1.3	1.9 ± 1.2	1.4 ± 1.2	1.7 ± 1.2	.161
3	2.3 ± 1.0	3.0 ± 0.5	2.8 ± 0.8	2.6 ± 0.8	2.8 ± 0.8	.162
5	1.2 ± 1.1	1.2 ± 1.1	1.1 ± 0.9	1.8 ± 1.2	1.2 ± 1.0	.087
6	2.2 ± 0.5	2.7 ± 1.0	2.6 ± 0.9	2.4 ± 0.9	2.5 ± 0.9	.457
7	2.0 ± 1.5	1.9 ± 0.8	2.3 ± 0.9	1.9 ± 1.0	2.1 ± 1.0	.227
8	2.1 ± 0.8	2.1 ± 0.6	2.0 ± 0.7	1.8 ± 0.7	2.0 ± 0.7	.377
9	2.1 ± 1.2	2.2 ± 0.9	2.1 ± 0.8	2.2 ± 0.7	2.1 ± 0.8	.813
10	2.6 ± 1.4	3.6 ± 1.6	3.7 ± 2.0	4.2 ± 1.7	3.7 ± 1.9	.084
12	2.6 ± 2.3	3.2 ± 1.6	2.8 ± 1.1	2.9 ± 1.0	2.8 ± 1.2	.129
13	2.1 ± 1.2	2.6 ± 1.0	2.6 ± 0.9	2.8 ± 1.0	2.6 ± 0.9	.427
14	2.1 ± 1.2	3.0 ± 1.0	2.7 ± 0.7	2.7 ± 0.7	2.7 ± 0.8	.227

*Values are mean ± standard deviation.

Table 2. Analysis of the cement thickness for six sizes of the femoral component

Femoral zone	Cement thickness (mm)*						P Value
	CDH Precoat (n = 8)	Small† or Size 1‡ (n = 14)	Small Plus† or Size 2‡ (n = 42)	Medium† or Size 3‡ (n = 36)	Large† or Size 4‡ (n = 11)	Large Plus† or Size 5‡ (n = 2)	
1	1.3 ± 0.8	1.9 ± 0.7	2.2 ± 0.7	2.2 ± 0.8	2.0 ± 0.8	2.0 ± 0.8	.087
2	1.4 ± 1.0	1.6 ± 1.1	1.7 ± 1.2	1.8 ± 1.3	1.8 ± 1.2	2.4 ± 1.1	.838
3	2.3 ± 1.0	2.8 ± 0.7	2.8 ± 0.7	2.8 ± 0.9	3.0 ± 0.9	2.0 ± 1.7	.638
5	1.2 ± 1.1	1.4 ± 1.2	1.2 ± 1.0	1.0 ± 0.7	1.7 ± 1.4	2.0 ± 1.7	.894
6	2.2 ± 0.5	2.6 ± 0.9	2.6 ± 0.9	2.6 ± 0.8	2.4 ± 1.0	2.4 ± 1.1	.845
7	2.0 ± 1.5	2.1 ± 1.0	2.0 ± 1.0	2.4 ± 0.9	2.2 ± 0.8	1.8 ± 1.3	.498
8	2.1 ± 0.8	2.0 ± 0.8	2.1 ± 0.7	1.8 ± 0.7	1.8 ± 0.7	2.2 ± 1.7	.534
9	2.1 ± 1.2	2.3 ± 0.7	2.1 ± 0.7	2.0 ± 0.8	2.3 ± 0.9	2.8 ± 2.5	.766
10	2.6 ± 1.4	3.9 ± 2.1	3.5 ± 1.8	4.0 ± 2.1	3.9 ± 1.5	4.3 ± 3.8	.351
12	2.6 ± 2.3	3.0 ± 1.2	2.8 ± 1.1	2.9 ± 1.1	3.1 ± 1.4	2.3 ± 2.1	.450
13	2.1 ± 1.2	2.8 ± 1.0	2.5 ± 0.9	2.6 ± 0.9	2.7 ± 1.0	2.7 ± 1.3	.740
14	2.1 ± 1.2	2.8 ± 0.7	2.7 ± 0.7	2.8 ± 0.7	2.7 ± 0.9	3.5 ± 2.1	.420

*Values are mean ± standard deviation.

†Harris Precoat or Precoat Plus stem

‡Elite Plus stem

Table 3. Relationship between four types of the femoral component and various factors

Factors	CDH Precoat (n = 8)	Precoat (n = 15)	Precoat Plus (n = 68)	Elite Plus (n = 22)	Total (n = 113)	P Value
Follow-up (mean, range)	11.6y (9–14y)	14.0y (11.5–17y)	10.9y (7–15y)	8.9y (7–10y)	11.0y (7–17y)	
Canal filling ratio (%)*	72.0 ± 7.7	74.2 ± 9.2	75.9 ± 8.2	75.4 ± 8.4	75.3 ± 8.3	.637
Deep infection (n, %)	0 (0%)	0 (0%)	1 (1%)	0 (0%)	1 (1%)	.881
Presence of femoral radiolucent lines (n, %) [†]	2 (25%)	5 (33%)	16 (24%)	7 (32%)	30 (27%)	.802
Presence of femoral osteolysis (n, %) [†]	0 (0%)	1 (7%)	3 (4%)	1 (5%)	5 (4%)	.549
Postoperative dislocation (n, %)	2 (25%)	1 (7%)	6 (9%)	1 (5%)	10 (9%)	.365

*Values are mean ± standard deviation.

[†]Except one hip with removal of the femoral component for deep infection.