

# AMCoR

Asahikawa Medical University Repository <http://amcor.asahikawa-med.ac.jp/>

JAMA ophthalmology (2013.11) 131(11):1481-1482.

Fundus Video of Retinal Migraine

Isao Ota, Kiyomi Kuroshima, Taiji Nagaoka

# Letters

## RESEARCH LETTER

### Fundus Video of Retinal Migraine

Retinal migraines are characterized by attacks of fully reversible monocular vision loss associated with migraine headaches, and these phenomena are rare. Furthermore, because



Video at  
jamaophthalmology.com

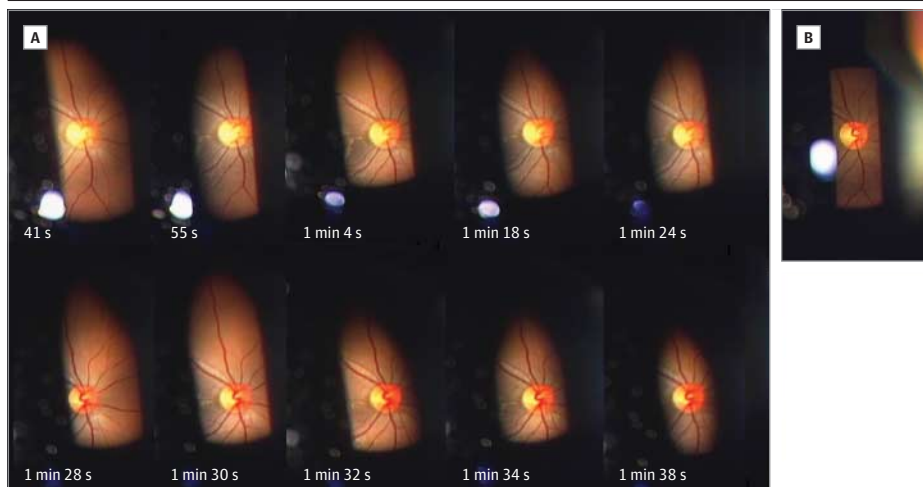
it is difficult to observe dynamic changes in fundus images during transient vision loss, retinal vasospasm rarely has been documented photographically.<sup>1-4</sup> Using videos, we documented a case of retinal vasospasm during a transient episode of monocular vision loss in a patient with a history of migraine.

**Report of a Case** | A 29-year-old healthy woman described a 10-year history of migraine with aura; her mother had also had mi-

graines. The patient described a visual aura of twinkling stars that preceded the headaches by several hours. The recurrent monocular vision loss (whiteout) resolved in 2 to 5 minutes in the right eye. She visited us after the third episode. Visual acuity measured during the ophthalmologic examination was 20/15 OU. During the slitlamp examination, visual acuity decreased to light perception OD during the fourth, fifth, and sixth attacks. Four attacks occurred over several hours after the examination.

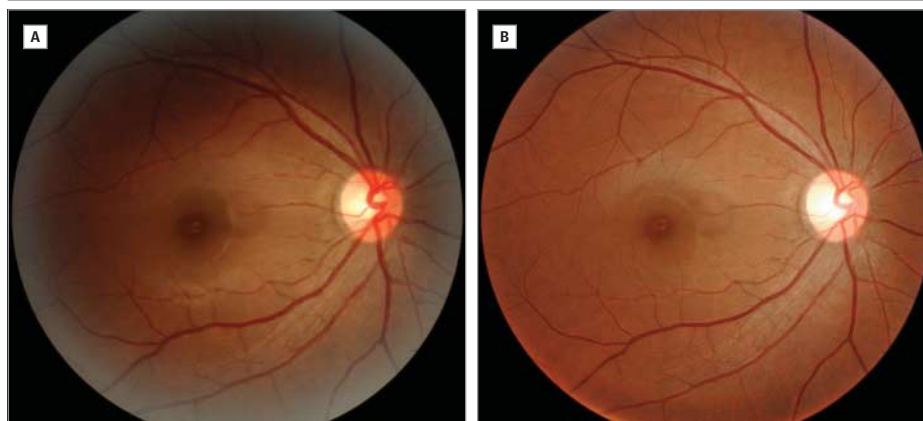
We recorded the fundus for 1 minute 55 seconds during the sixth attack (**Video 1**); the video shows the dynamic changes in the retinal arteries and veins (narrowing, reperfusion, and dilation) and alterations in the color of the optic disc and choroid. The images captured from the video show dynamic fundus changes over time (**Figure 1**). The retinal arteries and veins were extremely narrow compared with those in the control image. The blood columns in the veins were interrupted and had a rouleaux formation. The optic disc was pale and the choroid

Figure 1. Dynamic Fundus Changes and Control Image



A, Dynamic fundus changes over time during the attack in the images captured from the video. The times indicate when the images were obtained after the onset of the attack. B, A control image obtained 1 month after the attack.

Figure 2. Fundus Photographs of Right Eye



Images of the right eye obtained with a regular fundus camera taken immediately after the attack (A) and 1 month after the attack under normal conditions (B).

seemed to be dark. The narrowing of the retinal vessels and disc pallor diminished gradually over time. In the late phase of the attack (after 1 minute 28 seconds), the retinal vessels were dilated and the disc was hyperemic. **Video 2** and **Video 3** show the reperfusion of the retinal circulation in the late phase. The images obtained immediately after the attack (**Figure 2**) show the dilated retinal vessels in the right eye. The images show that the retinal veins and arteries in the right eye were more dilated than those in the left eye (not shown) or those obtained under normal conditions 1 month after the attack.

No hypercoagulability was identified with hematologic and serologic testing. Findings on neurologic tests and magnetic resonance imaging of the brain were normal. The patient was treated with propranolol hydrochloride because of an allergy to lomerizine hydrochloride, and the retinal migraines have not recurred.

**Discussion** | Most cases of previously documented retinal vasospasms have been associated with emboli or systemic diseases.<sup>1,3,4</sup> Most cases reported to be retinal migraine were cases of presumed retinal vasospasm, and this disorder is exceedingly rare.<sup>5</sup> Because our patient had no systemic disease except migraine and no embolus, the attacks were likely to have been primary vasospasms. The images clearly show vasospasm in a patient with a history of migraine with aura, which supports the belief that retinal migraine is a distinct entity. Individual cases of transient monocular vision loss have varied in the main component of vasoconstriction.<sup>6</sup> In our case, diffuse narrowing of the retinal vessels may have represented decreased blood flow in the central retinal artery, and disc pallor and a dark choroid may have indicated decreased posterior ciliary circulation. Therefore, we speculated that the main component of the vasoconstriction may be the ophthalmic artery and that marked retinal vasodilation at the end and immediately after the attack may represent compensation for hypoxia of the retinal tissues.

Isao Ota, MD, PhD  
Kiyomi Kuroshima, MD  
Taiji Nagaoka, MD, PhD

**Author Affiliations:** Department of Ophthalmology, Asahikawa Red Cross Hospital, Asahikawa, Japan (Ota); Department of Neurology, Asahikawa Red Cross Hospital, Asahikawa, Japan (Kuroshima); Department of Ophthalmology, Asahikawa Medical University, Asahikawa, Japan (Nagaoka).

**Corresponding Author:** Isao Ota, MD, PhD, Department of Ophthalmology, Asahikawa Red Cross Hospital, 1-1 Akebono, Asahikawa, 070-8530, Japan (iota@asahikawa-rch.gr.jp).

**Published Online:** September 5, 2013.  
doi:10.1001/jamaophthalmol.2013.4686.

**Author Contributions:** *Study concept and design:* All authors.  
*Acquisition of data:* Ota, Kuroshima.  
*Analysis and interpretation of data:* Ota, Kuroshima.  
*Drafting of the manuscript:* All authors.  
*Critical revision of the manuscript for important intellectual content:* Ota.  
*Obtained funding:* Ota.  
*Administrative, technical, or material support:* Ota, Kuroshima.  
*Study supervision:* Nagaoka.

**Conflict of Interest Disclosures:** None reported.

1. Humphrey WT. Central retinal artery spasm. *Ann Ophthalmol*. 1979;11(6):877-881.

2. Kline LB, Kelly CL. Ocular migraine in a patient with cluster headaches. *Headache*. 1980;20(5):253-257.

3. Winterkorn JMS, Kupersmith MJ, Wirtschatter JD, Forman S. Brief report: treatment of vasospastic amaurosis fugax with calcium-channel blockers. *N Engl J Med*. 1993;329(6):396-398.

4. Bernard GA, Bennett JL. Vasospastic amaurosis fugax. *Arch Ophthalmol*. 1999;117(11):1568-1569.

5. Hill DL, Daroff RB, Ducros A, Newman NJ, Biouesse V. Most cases labeled as "retinal migraine" are not migraine. *J Neuroophthalmol*. 2007;27(1):3-8.

6. Petzold A, Islam N, Plant GT. Video reconstruction of vasospastic transient monocular blindness. *N Engl J Med*. 2003;348(16):1609-1610.

## Novel Compound Heterozygous Mutations Resulting in Cone Dystrophy With Supernormal Rod Response

Cone dystrophy with supernormal rod response (CDSRR) (RCD3B, OMIM #610356) was first described in 2 siblings by Gouras et al<sup>1</sup> in 1983. In subsequent reports, it has been characterized as a rare autosomal recessive retinal disorder associated with a delayed and markedly decreased cone and rod response that exhibits an exaggerated, or superthreshold, rod electroretinogram (ERG) in response to higher stimulus levels.<sup>2</sup> Reports of CDSRR commonly describe an early onset of dyschromatopsia, photophobia, and central scotoma with poor best-corrected visual acuity.<sup>3</sup> Associated signs and symptoms include nyctalopia, nystagmus, and macular retinal pigment epithelium changes.<sup>3,4</sup>

Genetic studies have linked CDSRR to mutations in the potassium channel, subfamily V, member 2 gene (*KCNV2*), which is predominantly expressed in retinal photoreceptors and encodes a modulatory subunit of the Kv8.2 voltage-gated potassium channel.<sup>4</sup> Mutations in *KCNV2* may inhibit proper assembly of heteromeric voltage-gated potassium channels with a subsequent pathologically prolonged outward potassium current in the dark, causing an abnormality in photoreceptor membrane potentials.<sup>5</sup> The exclusive link of CDSRR to *KCNV2* mutations is a notable contrast from the majority of inherited retinal disorders, which display genetic heterogeneity.

**Methods** | A complete ophthalmic examination by a retinal physician (S.H.T.) was performed, including fundus autofluorescence using scanning laser ophthalmoscopy (Heidelberg retinal angiograph; Heidelberg Engineering), microperimetry (MP1; Nidek Technologies), and spectral-domain optical coherence tomography (Spectralis optical coherence tomography/scanning laser ophthalmoscopy; Heidelberg Engineering). An electrophysiological assessment was performed using the Espion 5 system (Diagnosys). Full-field electroretinograms (ERGs) were recorded according to the standards of the International Society for Clinical Electrophysiology of Vision.

Blood samples were genetically screened at Casey Eye Institute Laboratory, Portland, Oregon, for *KCNV2* coding region mutations that cause disease. All exons and flanking introns of *KCNV2* were directly sequenced on the ABI 3100XL DNA sequencer (Applied Biosystems), and detected variants were analyzed for evolutionary conservation by the prediction programs PolyPhen-2 and SIFT.

**Report of a Case** | A 47-year-old man presented with decreased visual acuity and a history of hemeralopia and photophobia