

AMCoR

Asahikawa Medical University Repository <http://amcor.asahikawa-med.ac.jp/>

BMJ case reports (2014.5) .:

Tranexamic acid-induced ligneous conjunctivitis with renal failure showed reversible hypoplasminogenaemia.

Young-seok Song, Naohiro Izumi, Luke Benjamin Potts, and Akitoshi Yoshida

A Case of Tranexamic acid-Induced Ligneous Conjunctivitis with Renal Failure showed Reversible Hypo-Plasminogenemia.

Young-seok Song MD, Naohiro Izumi MD, Luke Benjamin Potts BS,
and Akitoshi Yoshida MD

Y. Song, A. Yoshida

Department of Ophthalmology, Asahikawa Medical University, Asahikawa, Japan

Address: Midorigaoka Higashi 2-1-1-1, Asahikawa 078-8510, Japan

N. Izumi

Eye Clinic, Hakodate Goryokaku Hospital , Hakodate, Japan

Address: Goryokaku 38-3, Hakodate 040-8611, Japan

T. Ikeda

Pathology Center, Hakodate Goryokaku Hospital , Hakodate, Japan

Address: Goryokaku 38-3, Hakodate 040-8611, Japan

L. B. Potts

College of Medicine, Texas A&M Health Science Center, Texas A&M University Temple, TX

Address: 702 Southwest H.K. Dodgen Loop, Temple, TX 76504, USA

Corresponding author: Young-seok Song, MD, Department of Ophthalmology, Asahikawa Medical

University, Midorigaoka Higashi 2-1-1-1, Asahikawa 078-8510, Japan; Phone:+81-166-68-2543

e-mail: ysong@asahikawa-med.ac.jp

ABSTRACT

BACKGROUND

Ligneous conjunctivitis is a rare severe conjunctivitis characterized by fibrin-rich, “woody,” pseudomembranes on the tarsal conjunctiva complicated by congenital hypoplasminogenemia. A previous report suggested that ligneous conjunctivitis may result from tranexamic acid (TA)-induced “secondary” hypoplasminogenemia. However, the serum plasminogen level has not been confirmed in that scenario. We report for the first time a case of TA-induced ligneous conjunctivitis with reversible hypoplasminogenemia.

CASE REPORTS

A 70-year-old woman developed a gastric ulcer that was treated with oral TA. After 5 weeks of treatment, the patient presented with bilateral pale yellow pseudomembranes on the palpebral conjunctivae. Hematologic analysis showed hypoplasminogenemia. We diagnosed ligneous conjunctivitis. TA was discontinued after 14 weeks after the gastric ulcer symptoms resolved. Six weeks after discontinuation of therapy, the pseudomembranes regressed and the serum plasminogen level returned to the normal range.

CONCLUSIONS

TA should be considered a possible etiology in the setting of unresolving ligneous conjunctivitis.

CASE PRESENTATION

A 70-year-old Japanese female with chronic renal failure presented with a three-day history of pain and pruritus in the left eye and was diagnosed with peripheral corneal infiltration, started on 0.5% levofloxacin hydrate and 0.1% fluorometholone drops. After one week with this therapeutic regimen, it had completely resolved. However, during this time the patient developed a gastric ulcer, and was treated with oral tranexamic acid (Transamin ®, 750 mg/day). Six weeks after initial presentation to our clinic, which coincided with approximately five weeks of tranexamic acid therapy, the patient presented with a four-day history of bilateral severe eye pain. She had no other ophthalmic complaints. Slit lamp examination was normal with the exception of bilateral pale yellow pseudomembranes on the upper palpebral conjunctiva (Figure 1). Dilated fundoscopic examination was unremarkable bilaterally. Pseudomembranes were swabbed and cultured, and found to be negative for bacteria. The lesions were resected bilaterally, and histopathologic examination demonstrated fibrin accumulation and an inflammatory cell infiltrate. There was no evidence of fungi and staining for amyloid was negative. Plasma plasminogen activity was low at <25% (normal: 73-94%). A diagnosis of ligneous conjunctivitis was made, and treatment with daily topical cyclosporine (0.1%) was initiated. There were multiple recurrences and repeat resections of the pseudomembranes over a period of nine weeks. Fourteen weeks after beginning tranexamic acid, the drug was discontinued due to resolution of gastric ulcer symptoms. Topical cyclosporine was discontinued at ten weeks after discontinuation of tranexamic acid. Six weeks after discontinuing tranexamic acid therapy, the pseudomembranes had almost completely regressed (Figure 2). Plasma plasminogen activity had also returned to within the normal range at this time (74%). Thirty weeks after discontinuation of tranexamic acid, there had been no recurrence of pseudomembrane.

DISCUSSION

Ligneous conjunctivitis is a rare form of chronic conjunctivitis characterized by the development of fibrin-rich, “woody”, (e.g., ligneous) pseudomembranes on the tarsal conjunctiva[1]. Corneal involvement is a common complication with this condition, and may lead to blindness as a result of scarring, vascularization, keratomalacia, and corneal perforation[1]. The diagnosis of ligneous conjunctivitis is made based on the clinical appearance and histopathologic demonstration of fibrinous pseudomembranes with inflammatory cell infiltrate[1]. Infectious causes for pseudomembrane formation must be ruled out prior to diagnosing ligneous conjunctivitis[1]. Low plasma plasminogen activity further confirms the

diagnosis[1]. Herein, we describe a case of recurrent ligneous pseudomembrane formation resulting from treatment with tranexamic acid, an anti-fibrinolytic agent. The clinical and laboratory findings were consistent with a diagnosis of ligneous conjunctivitis. The relationship between hypoplasminogenemia and ligneous conjunctivitis has been firmly established in the past[1]. Low plasmin activity leads to membrane or pseudomembrane formation due to inadequate fibrinolysis[2]. Activation of the fibrinolytic system depends on the zymogen plasminogen, a serine protease present in plasma[3]. Plasminogen is predominantly produced by the liver and circulates in the blood. It is converted to plasmin by tissue-plasminogen activator (t-PA) or urokinase-type plasminogen activator (u-PA)[4]. Plasmin plays an important role in intravascular and extravascular fibrinolysis, wound healing and tissue remodeling[3]. The main substrate for plasmin is fibrin and an absence of plasmin leads to pathological clot formation[5]. Congenital plasminogen deficiency is an autosomal recessive disorder that has a variety of systemic manifestations, including gingivitis, renal calculi, vulvovaginitis, respiratory disease, otitis media and hydrocephalus among others. However, ligneous conjunctivitis is by far the most common clinical manifestation of hypoplasminogenemia[1]. Because our patient had no family history of hypoplasminogenemia, and there were no other systemic manifestations, a congenital plasminogen deficiency was deemed unlikely. Additionally, serum plasminogen activity rose to within the normal range after cessation of tranexamic acid.

Tranexamic acid is a synthetic derivative of the amino acid lysine that has been used for treatment multiple types of bleeding diatheses, including intra- or post-operative bleeding, menorrhagia, and pulmonary or renal hemorrhage. It has also been used in cases of oral mucosal aphthae associated with stomatitis and pharyngolaryngitis[6]. Tranexamic acid exerts its antifibrinolytic effect by blocking the interaction of plasmin with fibrin by blocking the lysine binding sites on the kringle domains of plasmin. This prevents formation of the fibrin-plasmin complex, thus mitigating fibrinolysis[2, 6]. Interestingly, Diamond et al[7] previously suggested that the drug could potentially cause ligneous conjunctivitis via its antifibrinolytic effects. Herein, we report for the first time a case of ligneous conjunctivitis associated with reduced serum plasminogen activity that resolved upon cessation of tranexamic acid therapy, which seems to support the concept that the antifibrinolytic property of this drug may lead to development of this type of conjunctivitis in some patients.

There are only one report of ligneous conjunctivitis associated with tranexamic acid[7], although tranexamic acid is a widely used drug[6]. We hypothesize that our patient may have been at increased risk for the adverse effects of tranexamic acid secondary to renal dysfunction.

The drug is metabolized in the kidney, and some reports have suggested that the drug effects may be increased in patients with renal impairment[6]. Hence, although the patient was taking the usual therapeutic dose of tranexamic acid, her blood levels may have been significantly higher. Hence, we suspect that the ligneous conjunctivitis was a manifestation of increased circulating levels of tranexamic acid. Consistent with this hypothesis, resolution of signs and symptoms only occurred after discontinuation of tranexamic acid. Use of tranexamic acid should be considered as a possible etiology in the setting of unresolving ligneous conjunctivitis. Moreover, caution should be exercised in the use of tranexamic acid as it may contribute to the development of ligneous conjunctivitis that is not amenable to typical treatment modalities.

REFERENCES

1. Schuster V, Seregard S (2003) Ligneous conjunctivitis. *Surv Ophthalmol* 48: 369-388
2. Schuster V, Hugel B, Tefs K (2007) Plasminogen deficiency. *J Thromb Haemost* 5: 2315-2322 DOI 10.1111/j.1538-7836.2007.02776.x
3. Castellino FJ, Ploplis VA (2005) Structure and function of the plasminogen/plasmin system. *Thromb Haemost* 93: 647-654 DOI 10.1267/THRO05040647
4. Bugge TH, Flick MJ, Danton MJ et al(1996) Urokinase-type plasminogen activator is effective in fibrin clearance in the absence of its receptor or tissue-type plasminogen activator. *Proc Natl Acad Sci U S A* 93: 5899-5904
5. Collen D, Lijnen HR (1991) Basic and clinical aspects of fibrinolysis and thrombolysis. *Blood* 78: 3114-3124
6. McCormack PL (2012) Tranexamic acid: a review of its use in the treatment of hyperfibrinolysis. *Drugs* 72: 585-617 DOI 10.2165/11209070-000000000-00000
7. Diamond JP, Chandna A, Williams C et al (1991) Tranexamic acid-associated ligneous conjunctivitis with gingival and peritoneal lesions. *Br J Ophthalmol* 75: 753-754

LEGENDS

Figure 1: Upper palpebral conjunctiva after six weeks of tranexamic acid use.

Pale yellow, thick pseudomembranes were observed in both eyes.

Figure 2: Upper palpebral conjunctiva six weeks after discontinuing tranexamic acid. There is dramatic improvement with only minimal pseudomembrane present at the left upper palpebral fornix of the conjunctiva.

FIGURES

Figure 1.

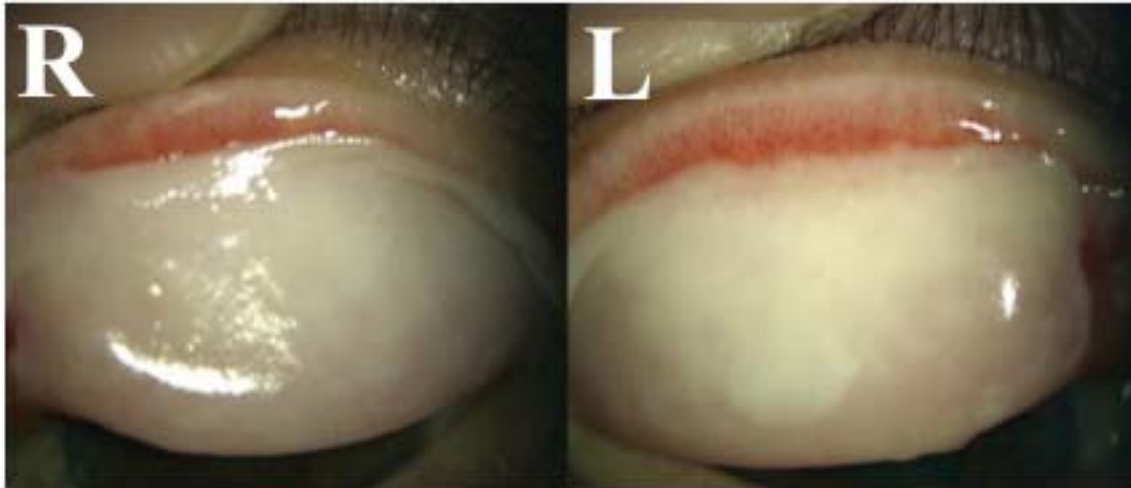


Figure 2.

