

# AMCoR

Asahikawa Medical University Repository <http://amcor.asahikawa-med.ac.jp/>

Annals of thoracic and cardiovascular surgery (2010.Aug) 16卷4号:273  
~275.

Recurrent diaphragmatic hernia 3 years after initial repair for traumatic  
diaphragmatic rupture: a case report

Kitada Masahiro, Ozawa Keisuke, Satoh Kazuhiro, Hayashi  
Satoshi, Sasajima Tadahiro

## Recurrent Diaphragmatic Hernia 3 Years after Initial Repair for Traumatic Diaphragmatic Rupture: A Case Report

Masahiro Kitada, MD, Keisuke Ozawa, MD, Kazuhiro Satoh, MD, Satoshi Hayashi, MD, and Tadahiro Sasajima, MD

We report herein a technique for the repair of recurrent diaphragmatic hernia after repair of diaphragmatic rupture. Although chest roentgenography and computed tomography in a patient who presented with postprandial abdominal pain demonstrated a left intrathoracic intestinal shadow, the hernia was disregarded. To repair a diaphragmatic rupture along with intrathoracic adhesions, we performed adjunctive thoracotomy coupled with laparotomy. This report demonstrates the need for consideration of previous injuries, the value of combined thoracotomy and laparotomy, and the utility of repair using nonabsorbable sutures in the management of diaphragmatic hernia. (*Ann Thorac Cardiovasc Surg* 2010; 16: 273–275)

**Key words:** rupture (diaphragm), diaphragm, trauma, hernias, suture

### Introduction

Diagnosis of traumatic diaphragmatic rupture is difficult and is often either missed or delayed, even in hemodynamically stable patients, because they are asymptomatic or have nonspecific complaints. Delayed presentation of traumatic diaphragmatic hernia often leads to a substantial delay in correct diagnosis. This is mainly caused by the low specificity of routine chest X-ray examinations, though a careful examination of radiological images can usually provide a clear indication. Differences in diagnoses often depend on the knowledge of any history of ruptures or hernias, especially with patients presenting no specific complaints. This report describes a case of delayed presentation of recurrent diaphragmatic hernia resulting from misdiagnosis in which repair was performed using combined thoracotomy and laparotomy.

*From First Department of Surgery, Asahikawa Medical University, Hokkaido, Japan*

Received March 18 2010; accepted for publication April 15, 2010  
Address reprint requests to Masahiro Kitada, MD: First Department of Surgery, Asahikawa Medical University, Midorigaoka-Higashi 2-1-1, Asahikawa, Hokkaido 078-8510, Japan.  
©2010 The Editorial Committee of *Annals of Thoracic and Cardiovascular Surgery*. All rights reserved.

### Case

A 61-year-old man was admitted after a traffic accident in March 2005 and underwent emergency surgery for rupture of the left diaphragm with pneumohemothorax and multiple fractures of the left ribs. An upper abdominal median incision was made, and diaphragmatic rupture was directly closed by interrupted sutures using 2-0 polyglactin absorbable stitches (Vicryl®; Ethicon, Somerville, NJ, USA). Postoperative course was uneventful, and the patient was discharged 3 weeks later. Although no postoperative complications were encountered, he presented 3 years later with upper abdominal pain and postprandial discomfort that kept worsening. On examination, chest roentgenography showed left diaphragmatic elevation, and conventional computed tomography (CT) demonstrated a left intrathoracic colon gas shadow (Figs. 1 and 2). We considered recurrence of the diaphragmatic hernia, but this didn't result in a definite diagnosis, probably because the history of diaphragmatic rupture was not elicited. Gastrofiberscopy showed no abnormality. A colonoscopy was reflected in the herniated intrathoracic colon in fluoroscopy (Fig. 3), but we canceled examination immediately. This established a definitive diagnosis of recurrent diaphragmatic hernia, and the patient was

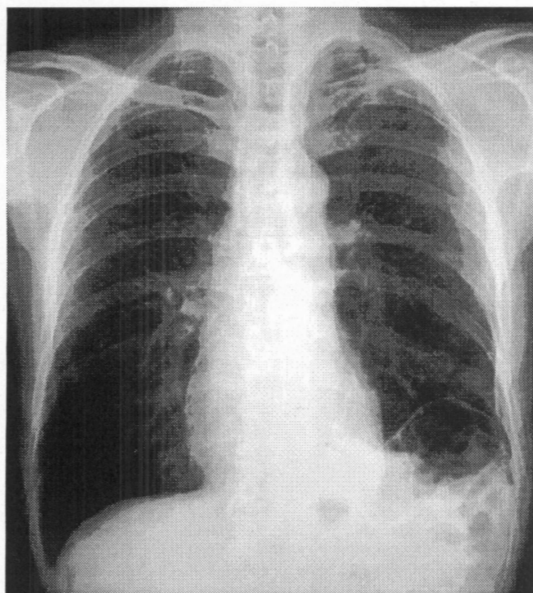


Fig. 1. Chest radiograph showed the gas image that allows suspicion of an existing bowel on the left diaphragm.

referred to this hospital for corrective surgery.

An upper midline laparotomy was made in the area of the initial operation, revealing minimal adhesions in the abdominal cavity and a large defect with herniated jejunum and transverse colon in the posterolateral area of the left diaphragm. Intrathoracic adhesions prevented retrieval of the herniated viscera into the abdomen, so for safe repositioning, an adjunctive minimum anterolateral thoracotomy 12 cm in length was made at the 9<sup>th</sup> intercostal space. Adhesions to the lung were dissected through the thoracotomy, and the herniated intrathoracic viscera were easily and safely retrieved into the abdominal cavity. After repositioning, an oval-shaped defect 8 cm in diameter was exposed through the thoracotomy; it was closed with interrupted horizontal mattress sutures using 2-0 polypropylene nonabsorbable stitches (Fig. 4). We used no reinforcer for interrupted suture, and the thoracotomy facilitated secure and adequate repair of the diaphragmatic defect. Postoperative course was uneventful with complete resolution of abdominal pain, and the patient was discharged 17 days after surgery. There have been no findings during the postoperative five years to suggest a recurrence.

### Discussion

Traumatic diaphragmatic rupture is reportedly seen in 0.8%–5.8% of all blunt trauma cases, 2.5%–5% of blunt

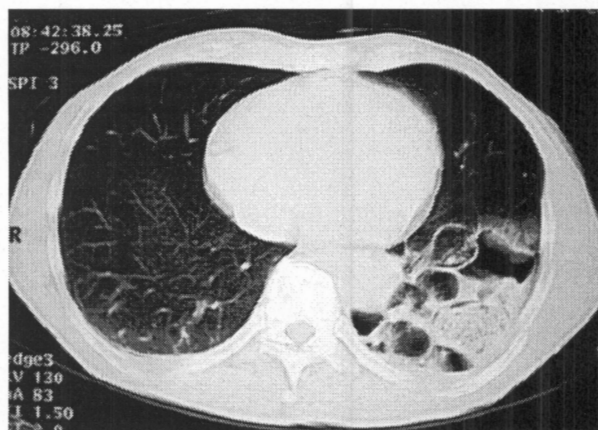


Fig. 2. Computed tomography showed the gas image that allows suspicion of an existing bowel in the thoracic space.

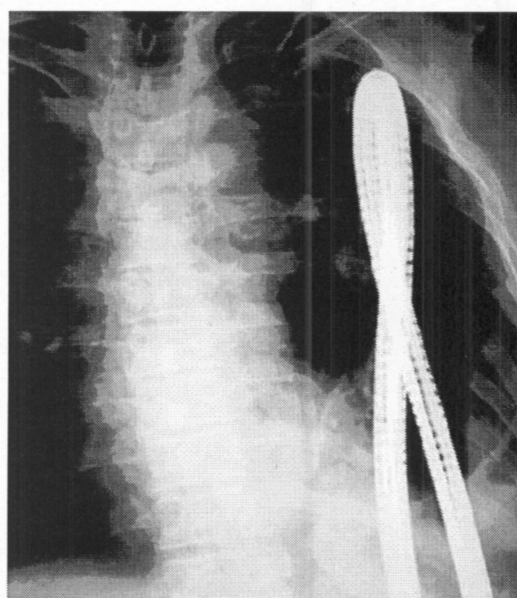


Fig. 3. Thoracoabdominal fluoroscopy demonstrating a colon fiberscope located in the herniated intrathoracic colon.

abdominal traumas, and 1.5% of blunt thoracic traumas.<sup>1)</sup> With blunt trauma, most ruptures occur in the posterolateral area of the left diaphragm, which is structurally weak.<sup>1)</sup> The right diaphragm is congenitally stronger and may also be protected by the liver. A review article found left-sided ruptures in 68.8% of patients, compared to right-sided ones in only 24.2%, bilateral in 1.5%, pericardial in 0.9%, and unclassified in 4.9%.<sup>2)</sup> Because early diagnosis of traumatic diaphragmatic rupture is difficult, many reports have described delayed presentation. The time until recurrence in the present patient was unclear, but

nonspecific complaints started from 3 years after initial surgery. Descriptions of recurrent diaphragmatic hernia, especially after repair of traumatic rupture, have been very limited, with only two recurrent cases in a review by Hanna et al.<sup>3</sup> In that study, only 13 (17.1%) of 76 patients alive at discharge could be assessed after repair surgery, revealing two recurrent cases. Although the true incidence of recurrence is unclear, the present rate of 15% suggests that recurrence after repair may not be rare.

Although most traumatic diaphragmatic hernias are diagnosed and successfully repaired at the time of initial injury,<sup>3</sup> correct diagnosis can often be delayed because blunt traumatic diaphragmatic hernia is relatively uncommon, and because patients may remain asymptomatic or display various nonspecific symptoms. The common initial diagnostic tool for diaphragmatic hernia is plain chest radiography, but this provides definitive diagnosis for only 17%–40% of patients.<sup>4</sup> In hemodynamically stable or delayed presentation cases, CT is the appropriate non-invasive diagnostic tool. However, the sensitivity of plain CT is variable, at 14%–82%, suggesting the likelihood of delayed diagnosis of associated diaphragmatic hernia. Delayed presentation of diaphragmatic hernia is often accidentally found during gastroscopy,<sup>5</sup> since most cases (47.8%) of hernias in the chest originate in the stomach.<sup>3</sup> In the present case, gastroscopy was initially performed for upper abdominal pain, but recurrent hernia was missed because the stomach was not herniated. McHugh et al. reported that barium meal and/or enema studies are useful when delayed presentation of diaphragmatic hernia is suspected.<sup>6</sup> Other reports of delayed or missed diagnoses suggest that the interpretation of examinations should be conducted with the possibility of diaphragmatic hernia in mind.

Among techniques for treating diaphragmatic rupture, laparotomy is required in more than half of cases in the traumatic phase.<sup>1</sup> For the present case, laparotomy was used first because of the likelihood of intra-abdominal adhesions, and adjunctive thoracotomy was effective not only in repositioning, but also in safe repair of the diaphragmatic defect. Another review paper<sup>3</sup> described two recurrent cases that had undergone initial repair with absorbable sutures, whereas the remaining 11 patients who underwent repair using nonabsorbable sutures showed no recurrence. Although that report provides no details, absorbable sutures were also used in the present case and could have been an important contributing factor to recurrence.

In conclusion, our case shows that whenever a complete

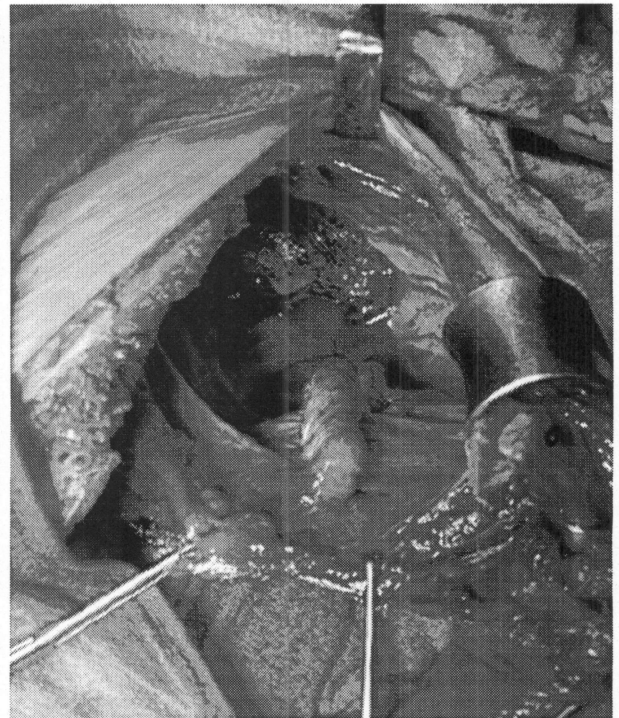


Fig. 4. Intrathoracic perioperative photography shows the state that finished a suture with a diaphragm.

relevant history is missing, a series of complementary noninvasive examinations is needed to ascertain the possibility of recurrence. Moreover, laparotomy and thoracotomy provide safe and effective treatment.

## References

1. Rubikas R. Diaphragmatic injuries. *Eur J Cardiothorac Surg* 2001; **20**: 53–7.
2. Shah R, Sabanathan S, Mearns AJ, Choudhury AK. Traumatic rupture of diaphragm. *Ann Thorac Surg* 1995; **60**: 1444–9.
3. Hanna WC, Ferri LE, Fata P, Razek T, Mulder DS. The current status of traumatic diaphragmatic injury: Lessons learned from 105 patients over 13 years. *Ann Thorac Surg* 2008; **85**: 1044–8.
4. Wirbel RJ, Mutschler W. Blunt rupture of the right hemi-diaphragm with complete dislocation of the right hepatic lobe: report of a case. *Surg Today* 1998; **28**: 850–2.
5. Junk S, Zegarski WZ, Bilinski PJ. Rupture of diaphragm involving herniated viscera following a blunt trauma diagnosed by gastrofiberscopy. *Endoscopy* 2001; **33**: 296.
6. McHugh K, Ogilvie BC, Brunton FJ. Delayed presentation of traumatic diaphragmatic hernia. *Clin Radiol* 1991; **43**: 246–50.