

# AMCoR

Asahikawa Medical University Repository <http://amcor.asahikawa-med.ac.jp/>

Journal of Anesthesia (2011) 25(1):133–134.

In reply : Comments on use of a Parker Flex-Tip tube® to facilitate intubation with the Pentax-AWS®

**Suzuki, Akihiro ; Ohmura, Tadahisa ; Kunisawa, Takayuki**

**In reply: Comments on use of a Parker Flex-Tip tube® to facilitate intubation with the Pentax-AWS®**

**Akihiro Suzuki\*1, Tadahisa Ohmura\*2, Takayuki Kunisawa\*2**

**\*1 Department of Emergency Medicine, Asahikawa Medical University**

**\*2 Department of Anesthesiology, Asahikawa Medical University**

Corresponding author

Tadahisa Ohmura, MD.

Department of Anesthesiology, Asahikawa Medical University

Midorigaoka higashi 2-1-1-1, Asahikawa, Hokkaido, Japan 0788510

Tel/FAX +81-166-68-2583/2589

e-mail: raohmura@gmail.com

To the editor:

First, we thank Dr Xue and Colleagues for their interest in our recent manuscript [1]. We wished to introduce the difficult intubation case that the Pentax-AWS blade was failed to reach the larynx and thus elevation of the epiglottis was unsuccessful. In our experience, this situation is not so common in Japanese population, probably because the design of the PBlade was determined from Japanese airway anatomy data. As we have already reported, if the blade tip was inserted toward vallecula, intubation was failed in high frequency with the standard bevel tube even if the good glottic opening was achieved with indirect epiglottic elevation [2]. In most cases, this situation can be easily handled with the maneuver described as Dr Xue. In our case, however, epiglottis can not be lifted directly and standard tube failed to pass the vocal cord. But when we used the Parker tube, it was able to pass through the vocal cord without impinging onto the epiglottis. Therefore, the title of the letter was determined as our previous manuscript [1].

To figure out the mechanism underlying this success, we conducted the mannequin study. We agree Dr Xue's opinion that the mannequin study is not as same as the situation we encountered. From the mannequin study, we can only say that "the Parker tube facilitates intubation when the AWS blade tip is inserted into vallecula". However, upon this mannequin study and photo image analysis of the blade tip, we thought we were able to show why this unique tube can be passed the vocal cord easily even when the AWS tip failed to lift the epiglottis directly.

Finally, we appreciate Dr. Xue's careful observation to our figure. As Dr. Xue pointed out, target symbol is not aligned to the vocal cord but aligned rightward from the glottic opening. We have already conducted the human study, and found this is one of the important features for successful intubation when the epiglottis was indirectly lifted with the AWS. When the target symbol is aligned to the glottic opening (Fig 1b), tube will be contacted to the epiglottis, results in failed intubation (Fig 1a). To increase the chance of success under this condition, camera's sightline should not be aligned perpendicular to the trachea but the tube direction should be (Fig 1c). To do so, target symbol seems not to be aligned to the vocal cords (Fig 1d) but allows tube to be advanced into the largest available space below the epiglottis, reducing the risk to impinge onto the epiglottis. AWS user should understand the angle discrepancy (about an angle of 15 degrees) between the camera and tube direction. When the intubation difficulty with the AWS was encountered, manipulate the blade direction and give way for the tube to be advanced (Fig 1c).

## **Reference**

1. Ohmura T, Suzuki A, Kurosawa A, Fujimoto K, Kunisawa T, Iwasaki H. Parker Flex-Tip Tube® facilitates intubation when the Pentax-AWS® fails to reach the larynx. *J Anesth.* 2010; 24: Epub ahead of print DOI 10.1007/s00540-010-1003-5
2. Suzuki A, Abe N, Sasakawa T, Kunisawa T, Takahata O, Iwasaki H. Pentax-AWS (Airway Scope) and Airtraq: big difference between two similar devices. *J Anesth.* 2008; 22:191-2.

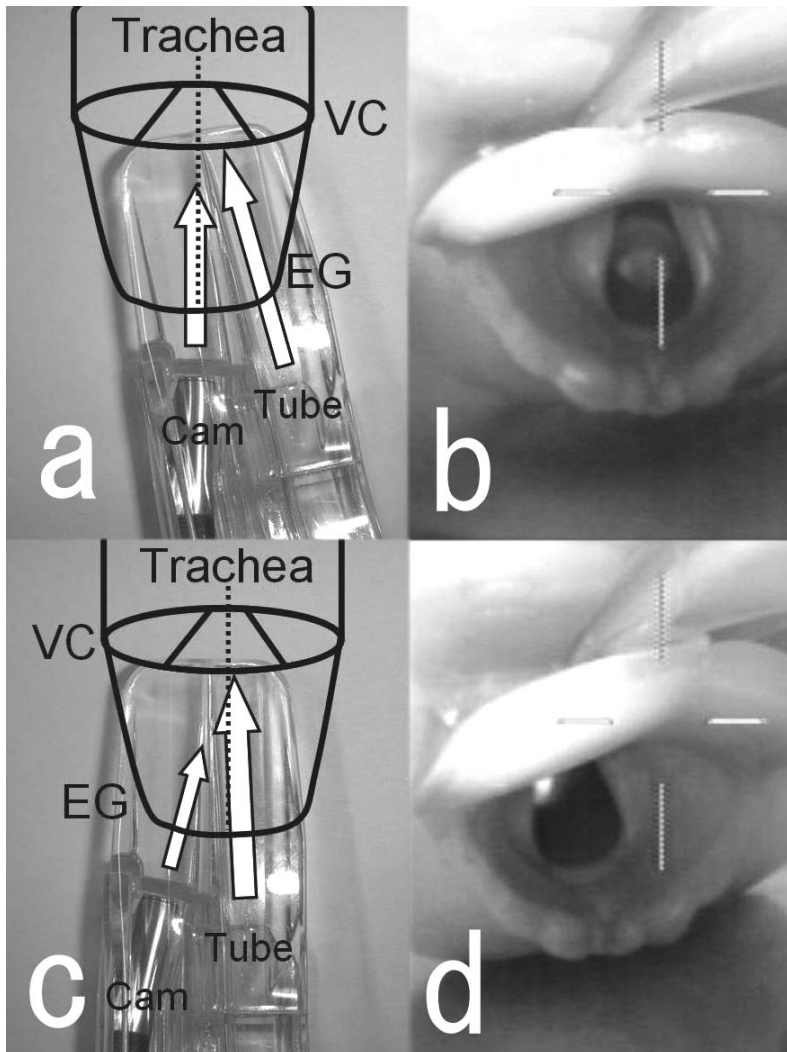


Figure 1

Relationship between the sightline of the camera and the route for tube passage.

- (a) When the sightline of the camera is perpendicular to the trachea, there may be more chance for the tube to be impinged onto the epiglottis although the target symbol seems to be aligned to the vocal cord.
- (b) Corresponding laryngeal view of the (a) on the monitor.
- (c) For successful intubation with the Pentax-AWS during indirect epiglottic elevation, camera should yield its way to the vocal cord. Although the target symbol does not seem to be aligned to the vocal cord, route for tube passage and the trachea is aligned.
- (d) Corresponding laryngeal view of (c).

VC: vocal cords, EG: epiglottis, Cam: sightline of the Camera, Tube: Direction of the tube to be advanced.