

AMCoR

Asahikawa Medical University Repository <http://amcor.asahikawa-med.ac.jp/>

Journal of Anesthesia (2010) 24(1): 124–127.

Displacement of the epiglottis during intubation with the Pentax-AWS Airway Scope®

Suzuki, Akihiro ; Katsumi, Norifumi ; Honda, Takashi ; Sasakawa,

Tomoki ; Kunisawa, Takayuki ; Henderson, John J. ; Iwasaki,

Hiroshi

Title Displacement of the epiglottis during intubation with the Pentax-AWS Airway scope®

List of Authors

Akihiro Suzuki¹, Norifumi Katsumi¹, Takashi Honda MD¹, Tomoki Sasakawa¹, Takayuki Kunisawa¹, John J. Henderson², and Hiroshi Iwasaki¹

1 Department of Anesthesiology and Critical Care Medicine, Asahikawa Medical College, Midorigaokahigashi 2-1-1-1, Asahikawa, Japan 078-8510

2 Department of Anaesthesia, Gartnavel General Hospital, Glasgow, UK

Corresponding author: Akihiro Suzuki MD. Department of Anesthesiology and Critical care medicine, Asahikawa Medical College, Midorigaoka higashi 2-1-1-1, Asahikawa, Japan 078-8510 Tel +81-166-68-2583 Fax +81-166-68-2589
Address e-mail to masuikasuzuki@yahoo.co.jp

Presentation: Content has not been presented any meetings in the past.

Financial Source: Departmental source only

Conflict of interest: No conflict of interests to be disclosed

Short title: Folding epiglottis caused by the Pentax-AWS®.

Key Words: Pentax-AWS, Airway Scope, folding epiglottis, epiglottis displacement

Abstract

The Pentax-AWS® system is a rigid indirect video laryngoscope with integrated tube guidance. Complications associated with this device are not well understood. We report two cases of epiglottis malposition during intubation with the Pentax-AWS®. The standard technique of using the Pentax-AWS® system involves direct elevation of the epiglottis for exposure of the vocal cords. The blade tip should be passed posterior to the epiglottis for laryngeal exposure, but the pressure on the anterior surface of the epiglottis by the tip can rarely happen even during the correct maneuver. Although the Pentax-AWS® provides clear images of the airway structures, it is sometimes difficult to observe the epiglottis continuously because the camera is located beneath the blade tip. Consequently, the view of the epiglottis from the camera may be impeded by the blade tip and may result in undiagnosed epiglottis malposition. AWS's structural feature and its approach to the larynx can be associated with increased chance of unexpected epiglottis folding. It is particularly important to confirm normal position of the epiglottis during withdrawal of the device to prevent this complication.

Introduction

The Pentax-AWS Airway Scope® system (AWS, HOYA, Tokyo, Japan) is a new indirect rigid video laryngoscope with integrated tube guidance which does not require the laryngoscopist to achieve a line of sight during laryngoscopy and tracheal intubation [1]. AWS can be used for both the normal and difficult airway.[2] During intubation, the glottis is visualized on the 2.4-inch built-in color-LCD monitor through the CCD camera positioned 1-inch away from the tip of the blade. Thus, intubation can be performed safely under vision. The technique recommended by the manufacture is that the tip of the AWS should be passed posterior to the epiglottis, which is elevated directly to, expose the glottis as with the other straight laryngoscope. However, since the camera is positioned beneath the tip of the blade, epiglottis is difficult to be watched after laryngeal exposure and during intubation procedure. We have experienced two cases of posterior displacement of the epiglottis which prolapsed into the trachea beside the tracheal tube during the intubation with the AWS.

Case presentations

Case 1

A 77-year-old woman (weighing 57 kg, height 153 cm) was admitted to our hospital for lumbar spine laminectomy under general endotracheal anaesthesia. She had no significant medical problems and the airway assessment gave no indication of potential problems. Anesthesia was induced with propofol (100 mg iv) and fentanyl (0.1mg iv) and neuromuscular blocking with vecuronium (6mg iv). After complete paralysis occurred, confirmed with the peripheral nerve stimulator, we performed intubation using the AWS connected to an external video-recorder. We inserted the AWS in the midline with 7.0 mm I.D. endotracheal tube (ETT) set in the channel. As we entered the blade into the oropharynx, the epiglottis was visualized. The laryngoscopist required a few attempts, including the advance and withdrawal maneuver of the AWS, to place the tip in the correct position posterior to the epiglottis. The laryngoscopist eventually achieved the visualization of the patient's vocal cords. The percentage of glottic opening (POGO) score being 80% **[Figure 1a]**, and he passed the ETT into the patient's trachea.

Immediately after ETT placement, the supervising anesthesiologist who also watched the procedure on the integrated LCD monitor of AWS suggested that the laryngoscopist might have displaced epiglottis into the trachea along with the ETT. We reviewed the videotaped procedure and confirmed this suggestion.**[Figure 1b]**

The laryngoscopist again inserted the AWS into the patient mouth, and could not see the epiglottis in its normal position. During careful withdrawal of ETT under vision, the epiglottis reappeared in view and returned to its normal position. There was no edema or bleeding observed on the surface of the epiglottis and so we performed the 4-hour operation. After surgery, we observed the epiglottis with the AWS again, but there was no significant abnormality. We withdrew the tube without any serious airway trouble. The patient complained of brief hoarseness and slight sore throat, but the symptoms disappeared within 24h.

Case 2

A 56-year-old woman (weighing 63 kg, height 160 cm) without having any complication was scheduled for breast cancer surgery. The anesthetic regimen was similar to Case 1. After insertion of the AWS, we observed the epiglottis on the monitor. The laryngoscopist manipulated the blade a few times to try to insert the tip posterior to the epiglottis. Finally he obtained the best laryngeal view, followed by ETT placement into the trachea. The supervising anesthesiologist watched the procedure through the built-in monitor and suspected that the laryngoscopist displaced the tip of the epiglottis into the trachea. He therefore asked the laryngoscopist to carefully withdraw the blade tip in order to confirm

the position of the epiglottis. This maneuver revealed that the tip of the epiglottis was partially inserted into the trachea. **[Figure 1c]** The laryngoscopist carefully withdrew the ETT under vision, and the epiglottis returned to its normal position. We observed no abnormality noted on the surface of the epiglottis and the laryngoscopist again inserted ETT to its optimal depth. In this case there was also no airway morbidity noted after surgery.

Discussion

The AWS has been used in clinical practice since 2006 in Japan and 2007 in other countries. Few complications associated with this new device have been described.

Epiglottis downfolding (posterior displacement of the epiglottis) is thought to be a rare complication but has been described with several airway techniques. The epiglottis lies within the bowl of the LMA in 60% of uses [3]. Once this “downfolding” occurs, the epiglottis can become ischemic and edematous [4] which may result in complete airway obstruction [5, 6].

Chance discovery by nasendoscopy of prolapse of the epiglottis into the larynx after intubation with a lighted stylet led the authors to conduct a prospective study in which they found a 10% incidence of brief epiglottis prolapse into the larynx with the lighted stylet despite use of a careful technique [7]. There was no significant damage in these cases in which the prolapse was rapidly relieved.

Prolapse of the epiglottis into the larynx has occurred with the classic [6] and intubating laryngeal mask [5,8]. In the latter case the prolapse was a chance finding during fiberoptic examination at the end of anesthesia and the epiglottis was edematous. Therefore, anesthesiologists should be cautious particularly when using these airway devices (such as LMA, lighted stylet) that involve “blind” technique.

However, even with the Macintosh laryngoscope, prolapse of the epiglottis has been described after tracheal intubation in an adult. In this case, the event was discovered during diagnostic laryngoscopy by the ENT surgeon [4].

Posterior displacement, leading in some cases to prolapse of the epiglottis into the larynx, is a consequence of pressure on the anterior surface of the epiglottis. It probably occurs much more frequently than is realized. It should not occur during techniques such as the straight laryngoscope and the Bullard and AWS devices in which the epiglottis is elevated directly.

The AWS is a new device which requires direct elevation of the epiglottis for laryngeal exposure. During glottic exposure with the AWS, the blade tip should be inserted posterior to the epiglottis, which is then elevated directly out of the line of sight of the glottis. In order to facilitate the passage of the tip posterior to the epiglottis, AWS blade should be passed along the posterior route through the airway, against the palate and posterior pharyngeal wall, as with the laryngeal mask airway insertion technique.

In the cases presented, novice laryngoscopists might have inserted the AWS along the anterior route. The blade tip was passed along the oral surface and then the base of the tongue, so that it passed anterior to the epiglottis and into the vallecula. This route is used for the conventional Macintosh laryngoscope. Once the blade tip is positioned in the

vallecula, further pressure from the blade tip may displace the epiglottis posteriorly as in the cases presented. However, pressure on the anterior surface of the epiglottis by the AWS tip can not be always prevented particularly when the floppy epiglottis or the narrow pharyngeal space exists. In this sense, users should be cautious in difficult airway cases such as small mandible or retrognathia.

In both cases the displacement was recognized immediately by the supervising anesthesiologist who was observing the built-in monitor. The ability to record and review the views is a diagnostic and teaching asset of the AWS.

The blade configuration may contribute to this complication. As in other rigid indirect laryngoscopes, the camera of the AWS is located beneath the blade tip in order to achieve a view of the glottis. Although direct elevation of the epiglottis used by the AWS is more reliable than the indirect Macintosh technique[9], it is sometimes difficult to see the epiglottis through the translucent blade tip from the AWS camera. In addition, blade configuration not allow laryngoscopist to observe the epiglottis directly through the oropharyngeal space.

We recommend the following maneuvers to reduce the risk of displacement of the epiglottis: 1) Choose the posterior route for AWS insertion 2) The shape and position of the epiglottis should be observed throughout manipulation of the blade tip. 3) Normal position of the epiglottis should be confirmed during withdrawal of the AWS. 4) More than one person should observe the intubation process, particularly when performed by novice personnel. 5) Jaw thrust should be applied when it is difficult to pass the tip posterior to the epiglottis.

Intubation procedure of the AWS is explained in for stages such as Insertion, Rotation, Elevation and Intubation[10]. We propose 5th stage, "Confirmation" of the anatomical structure, for safe intubation with this device. We have been experienced 3 cases of epiglottis displacement during 1000 intubations with the AWS and all of 3 cases were performed by trainees under supervision. The built-in monitor and ability to record and playback video images are features of the AWS which was useful for detecting the event.

References

1. Koyama J, Aoyama T, Kusano Y, Seguchi T, Kawagishi K, Iwashita T, Okamoto K, Okudera H, Takatsuna H, Hongo K. Description and first clinical application of AirWay Scope for tracheal intubation. *J Neurosurg Anesthesiol.* 2006;18:247-50
2. Suzuki A, Toyama Y, Katsumi N, Kunisawa T, Sasaki R, Hirota K, Henderson JJ, Iwasaki H. The Pentax AWS® rigid indirect video laryngoscope: clinical assessment of performance in 320 cases. *Anaesthesia.* 2008; 63: 641-7
3. J.R Brimacombe *Anatomy. Laryngeal Mask Anesthesia Principles and Practice*, 2nd ed. Philadelphia, Saunders; 2005:73-104.
4. Lin TS, Chen CH, Yang MW. Folding of the epiglottis an unusual complication to be recognized after laryngoscopic endotracheal intubation. *J Clin Anesth.* 2004;16:469-71
5. Murashima K, Fukutome T: Jaw thrust manoeuvre for repositioning the epiglottis down folded by the ILM. *Anaesthesia.*2000;55:921-2
6. Ramachandran K, Bhishma R. Unexpected difficult airway. *Anaesthesia.*2003; 58: 392-3
7. Aoyama K, Takenaka I, Nagaoka E, Kadoya T, Sata T, Shigematsu A. Potential damage to the larynx associated with light-guided intubation:a case and series of fiberoptic examinations. *Anesthesiology* 2001; 94:165–167.
8. Takenaka I, Aoyama K, Nagaoka E, Seto A, Nijima K, Kadoya T. Malposition of the epiglottis after tracheal intubation via the intubating laryngeal mask. *Br J Anaesth* 1999; 83:962–963.
9. Henderson JJ. Questions about the Macintosh laryngoscope and technique of laryngoscopy. *Eur J Anaesth* 2000;17:2-5
10. Suzuki A, Terao M, Fujita S and Henderson JJ. Tips for intubation with the Pentax-AWS rigid indirect laryngoscope in morbidly obese patients. *Anaesthesia* 2008; 63: 442-4

Figure Legend

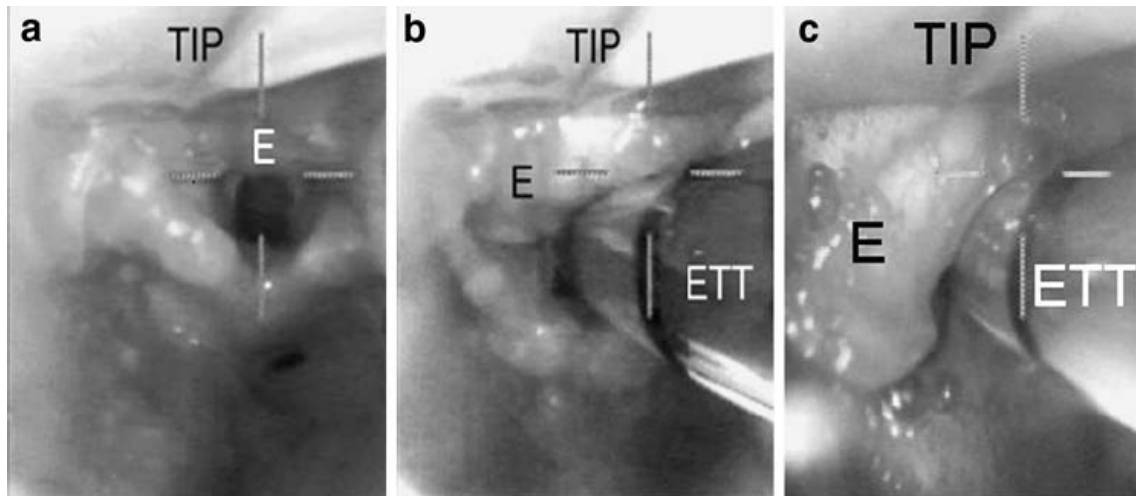


Figure 1. Laryngeal views obtained with the Pentax-AWS®

- Best laryngeal view achieved with the Pentax-AWS®. It is difficult to recognize but the epiglottis was folded into the trachea.
- View of the larynx after tracheal tube passage. Now its easier to recognize that the epiglottis was pushed into the laryngeal inlet along with the tracheal tube.
- In other case, epiglottis was partially folded in to the trachea, which was also recognized during withdrawal of the blade tip.

TIP: Tip of the AWS blade. ETT: Endotracheal tube. E: folding Epiglottis